

ARAŞTIRMALAR / RESEARCH ARTICLES

Effects of Thinner Inhalation on the Rat Nasal Mucosa

S. Zer Toros, S. Sezgin, T. Gökçeer, B. Toros, Ç. Akkaynak, O. Karaaslan, Ç. Çelikel

Sıçanlarda tiner inhalasyonunun burun mukozası üzerine etkileri

Sanayide yaygın olarak kullanılmaları nedeniyle imalattan günlük yaşama, birçok aşamada insanlar uçucu çözücülere inhalasyon, deri ve oral yol ile maruz kalmaktadırlar. Son yıllarda bu maddelerin özellikle de tinerin uyuşturucu amaçlı kullanılması söz konusu olmuştur. Diğer uyuşturucu maddelerin pahalı, temininin zor ve kullanımının yasak olması nedeniyle, daha çok sosyoekonomik düzeyi düşük ve ailevi problemleri olan gençler tarafından tiner tercih edilmektedir. Ayrıca bazı meslek gruplarında çalışan kişiler istemsiz olarak bu maddeye maruz kalmaktadırlar. Bu yüzden tinerin nazal mukoza üzerindeki etkilerini araştırmak giderek önem kazanmaktadır. Bu deneysel çalışma, tiner inhalasyonunun burun mukozası üzerinde oluşturduğu etkileri araştırmak amacı ile yapıldı. Çalışma grubu tiner inhalasyon sürelerine göre 4 gruba ayrıldı: 1., 2., 3. ve 4. gruplar sırasıyla 1, 3, 4 ve 5 hafta süre ile izlendi. Tiner inhalasyonuna maruz kalan hayvanlarda zamanla kilo kaybı görüldü. 4. grupta kilo kaybı diğer gruplarla ve kontrol grubu ile karşılaştırıldığında istatistiksel olarak anlamlı bulundu ($p<0.05$). Çalışma grubunda merkezi sinir sistemi üzerinde toksik etki olduğu gözlemlendi. 1. grupta en belirgin olan inflamatuvar yanıtın ilerleyen haftalarda azaldığı, ancak; istatistiksel olarak diğer gruplarla ve kontrol grubu ile karşılaştırıldığında anlamlı fark olmadığı saptandı ($p>0.05$). 1. haftadan itibaren skuamöz metaplazi, epitelial stratifikasyon ve tomurcuklanma gözlemlendi. Ancak 5. hafta sonuna kadar olan dönemde bu bulgularda istatistiksel olarak anlamlı artış tespit edilmedi ($p>0.05$). Epitelde villöz hipertrofi 2. grupta ortaya çıktığı, diğer gruplarda anlamlı bir artış gösterdiği belirlendi ($p<0.01$). Sonuç olarak, tiner inhalasyonuna maruz kalan burun mukozalarında skuamöz metaplazi ve epitelial hiperplazinin değişik formları olan stratifikasyon, tomurcuklanma ve villöz oluşumlar gözlemlenmiştir. Buna göre tinerin, diğer solunum sistemi organlarında olduğu gibi burun mukozası üzerinde de irritasyon yaptığı gösterilmiştir.

Anahtar Sözcükler: Tiner, nazal mukoza, toksisite.

Türk Otolarengoloji Arşivi, 2004; 42(3): 140-148

Sema Zer Toros, MD; Tanju Gökçeer, MD; Çınar Akkaynak, MD;
Osman Karaaslan, MD
Haydarpaşa Numune Hospital, Department of Otorhinolaryngology & Head and Neck Surgery, Istanbul

Saime Sezgin, MD; Çiğdem Çelikel, MD
Marmara University, Faculty of Medicine, Department of Pathology, Istanbul

Burak Toros, MD
Haydarpaşa Numune Hospital, Department of Gastroenterology, Istanbul

Abstract

People are exposed to volatile substances by inhalation, skin contact or oral intake, because these are widely used in industry. In recent years these substances are abused for their euphoric effects, especially thinner. Among these substances, thinner is the choice of the young people with low socioeconomic level and familial problems due to the expense, hardness to find and illegality of other drugs. In addition, many more are unwillingly exposed to these substances at work. So it's becoming more important to find out the effects of thinner inhalation on nasal mucosa. This experimental study was performed to evaluate the effects of thinner on the nasal mucosa. Four groups were dispersed due to inhalation periods. Exposure periods of the first, second, third and fourth groups were 1 week, 3 weeks, 4 weeks and 5 weeks respectively. Thinner inhaled animals lost weight within weeks. Loss of weight in the third group was found to be statistically significant compared to other groups and controls ($p<0.05$). Central nervous system toxicity was observed in the thinner inhaled groups. Inflammatory response which was most prominent in the first group decreased within weeks. But in comparison with other groups, the difference was statistically not significant ($p>0.05$). Squamous metaplasia, epithelial stratification and budding were formed by the first week; but no statistically significant increase was detected till the end of the 5th week ($p>0.05$). Epithelial villous hypertrophy appeared in the second group and became significantly prominent during following weeks in other groups as well ($p<0.01$). In conclusion, villous formations, budding, stratifications which are different forms of epithelial hyperplasia; and squamous metaplasia were observed in the nasal mucosa which exposed to thinner. So it was shown that thinner is harmful for the nasal mucosa as well as for the other organs of the respiratory system.

Key Words: Thinner, nasal mucosa, toxicity.

Turk Arch Otolaryngol, 2004; 42(3): 140-148

Introduction

Organic solvents are liquid substances which are widely used both at home in daily life and in industry. These solvents are principally present in paint thinner, lacquers, adhesive substances and typewriter correction fluids.¹

The thinner is misused, because it is cheap and easily available; and its possession ostensibly legitimate.^{1,2} Volatile substance inhalation is performed intentionally through a plastic bag or a bottle; or directly from the clothes after pouring of the substances on them. In acute intoxication, pleasurable sensations such as euphoria, feelings of well being, disinhibition followed by relaxation, vertigo, visual and auditory hallucinations, fatigue and confusion occurs.^{2,3} Also coughing, sneezing, flushing, increased salivation, diplopia, ataxia, slurring of speech, diminished reflexes and nystagmus may be observed.³ Long term exposure to these substances may damage the central nervous system (CNS), heart, liver, lungs and kidneys permanently.^{1,3,4}

The major risk in volatile substance inhalation is sudden death. This can be explained by four possible mechanisms; vagal stimulation, ataxia, respiratory depression and cardiac arrhythmias. Arrhythmias leading to cardiac arrest are thought to be the cause of most of the sudden deaths. Indirect causes like aspiration of vomitus or trauma may also be contributory.^{1,3}

The aim of this study was to study the effects of inhaled thinner on the nasal mucosa in experimental animals.

Materials and Methods

Forty male Wistar albino rats weighing between 110-160 gr were used throughout the experiment. All the rats were fed with standard diet and water. For the thinner inhalation, a glass cage (50 x 34 x 20 cm size) was designed. The common thinner in our industry which was composed of toluene (63%), acetone (13%), isobutyl acetate (10%) and butyl glycol (6.5%) was used in our experiment.

Rats were grouped according to the inhalation periods. First (n=5), second (n=6), third (n=5) and fourth (n=5) groups inhaled thinner for a week, 3 weeks, 4 weeks and weeks respectively. A control group of 15 rats was exposed to the same conditions without solvent and inhaled only room air.

Groups were exposed to 5 ml of thinner at room temperature for 20 minutes until the disappearance of righting reflex. Inhalation was performed twice a day at 9.00 and 15.00 for 1, 3, 4 and 5 weeks. At the end of their inhalation periods, rats were anesthetized with ketamine HCl (66 mg/kg intraperitoneal and 44 mg/kg IM) and decapitated. Rats' noses were dissected and their nasal mucosa were removed with the nasal bones, but without disturbing their integrity. Specimens were put in 10% formaldehyde solution.

Then they were fixed in buffered formaldehyde solution for 2 days. The nasal mucosa was dissected from the fixed tissue by a line passing through the teeth. Remaining tissue was kept in Shendon TBA Decalcifier for 3 days to be decalcified. Specimens were treated with water for 4-5 hours in order to wash out the acid. Tissues were dehydrated with alcohol solutions of various concentrations. Then they were buried in paraffin blocks. Specimens were sliced to 4 mm thickness and stained with Hematoxyline & Eosin. Since some tissues stained pale, slices were prepared to 7 mm thickness and stained with Mayer hematoxyline. All slices were examined under light microscope.

For statistical evaluation, Kruskal Wallis test, Dunn's Multiple Comparison test and Mann Whitney-U test were used in this study. The differences in the study group according to time were analyzed with Kruskal Wallis test; however, Dunn's multiple comparison test was used for the differences between the subgroups. Mann Whitney U test was used for two groups comparisons.

Results

A pilot study was performed with 4 rats. 5 ml of thinner was put in a cup and sealed to the glass

Table 1. Weights of study groups according to weeks.

	1st week	3rd week	4th week	5th week		p
	X±SD	X±SD	X±SD	X±SD	KW	
Weight	148±19.24	155±38.34	150±23.45	90±17.32	10.54	<0.05*

cage at room temperature and then, the rats were exposed to its vapour. At the beginning of inhalation rats gathered at a corner far away from the thinner cup. In the first 5 minutes period, animals displayed hyperactive behavior and active sniffing. They also tried to stand erect on their posterior legs. Between the 10-15 minutes period, they had difficulty in walking and after 15 minutes, they began to have difficulty in keeping the standing position. Many of them frequently swayed and crashed against the cage walls and one another. About the 20. minute, they lost their righting reflexes and did not respond to external stimuli. They were completely inactive. Two of them were taken out off the cage. The other two left in the cage died within the following 5

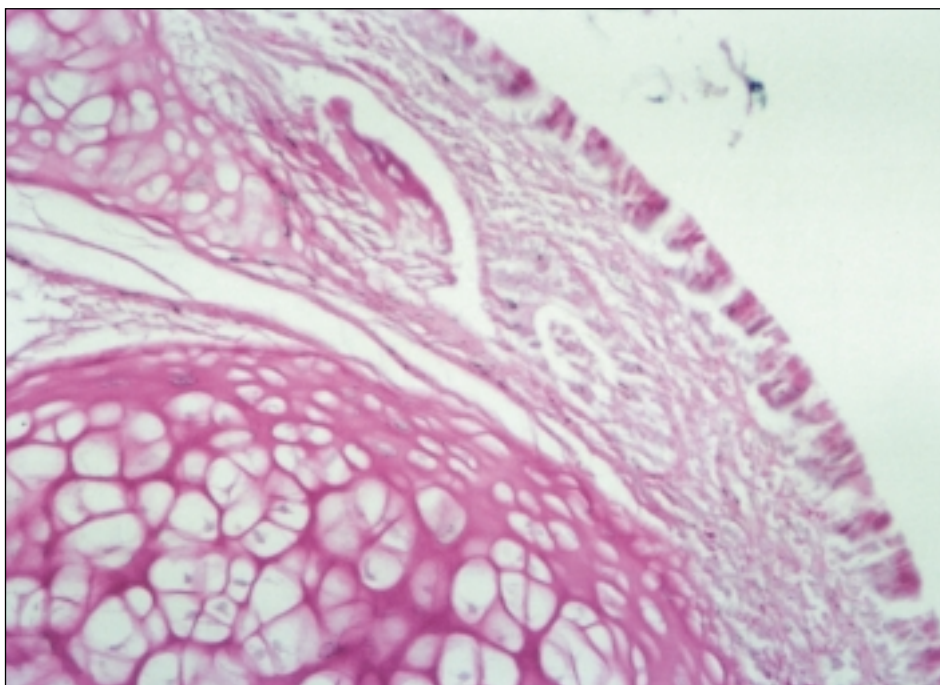
Table 2. Comparison of control group and group 4 by means of weight.

	Group 4	Control group		p
	X±SD	X±SD	MW	
Weight	90±17.32	211.3±36.03	1.24	0.001***

Table 3. Comparison of inflammatory changes in control group and group 4.

	Group 4	Control group		p
	X±SD	X±SD	MW	
Inflammation	1.2±0.44	1±0.96	31	>0.05

minutes. The survivors gradually returned to normal within 30 minutes.

**Figure 1.** Normal rat nasal mucosa (control group) (HE x20).

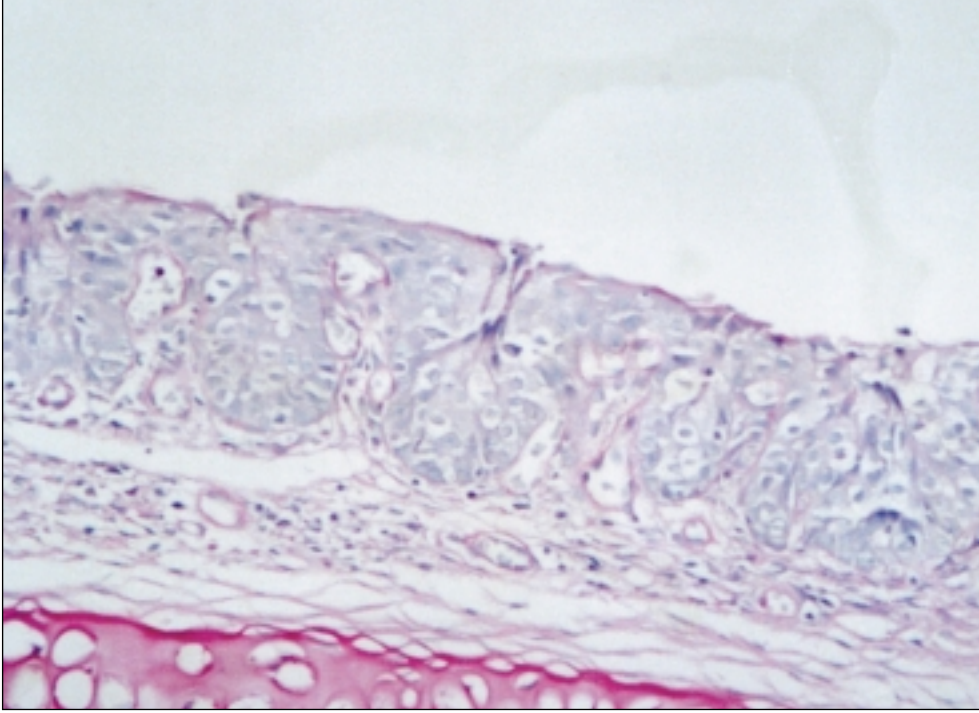


Figure 2. Nasal mucosa of group 1. Epithelial budding (epithelial projections into the stroma) (HE x20).

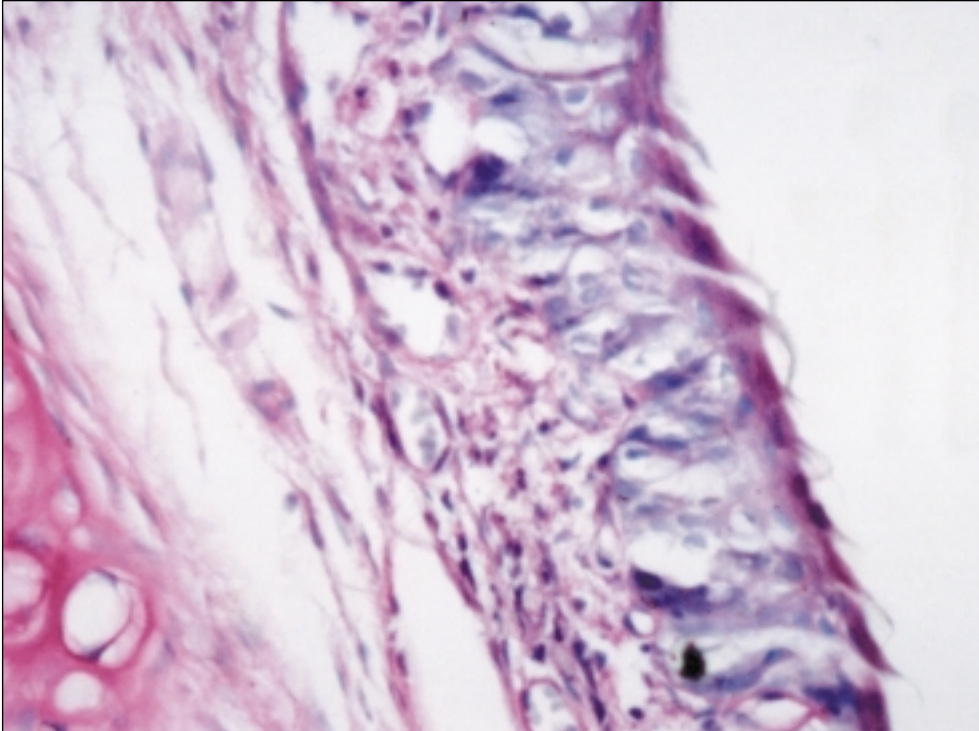


Figure 3. Nasal mucosa of group 2. Diffuse inflammatory cell infiltration and squamous metaplasia (HE x40).

During the study, the loss of hair and hemorrhages around the nostrils were observed in many rats even in the first week.

Weight measurements

All the rats were weighing 110-160 gr at the beginning of the study. Study groups were weighed at first, third, fourth and fifth weeks and control group was weighed at the end of the fifth week (Table 1 and 2).

When the weights of the rats were compared, a statistically significant decrease was found especially prominent at the fifth week ($p < 0.05$).

Furthermore when compared with the control group, the 4th group had lost statistically significant weight ($p < 0.001$).

In contrast to the study group which had lost weight, the control group reached to an average of 211.3 gr.

Pathological evaluation

In pathological evaluation, inflammation, exocytosis (presence of inflammatory cell within the epithelium), metaplasia, budding (epithelial projections into the stroma), epithelial stratification, villiform changes, mucous gland hyperplasia, basement membrane thickening and cilia loss were taken into consideration.

Generally the mucous gland hyperplasia, basement membrane thickening and the cilia loss were not observed at the slices. Although epithelial stratification, budding and villous formations were thought to be the early & late period findings of

hyperplasia, they were evaluated as different parameters because of morphological differences.

These histological changes were graded as mild (+), moderate (++) and severe (+++). In statistical scoring: No change (0), (+) 1, (++) 2 and (+++) 3.

Histopathologically, the control group had pseudostratified columnar epithelium. No changes were observed in this group except inflammatory changes in some animals. Inflammatory changes were not statistically significant between the control and the study groups ($p > 0.05$) (Table 3).

Inflammation was most prominent in the first week and decreased by the following weeks, but this was statistically insignificant ($p > 0.05$). The comparison of exocytosis, metaplasia, budding and stratification in the study groups revealed no statistical difference ($p > 0.05$). Villiform changes were observed in all groups except for the first group. Evaluations for villiform changes were determined to be significantly increased for third, fourth and fifth weeks ($p < 0.01$) (Figs. 1-5; Table 4).

Discussion

Studies in man and rats have shown that organic solvents cause physiological impairment of brain function following acute exposure in especially sensitive individuals. It has also been shown that chronic exposure to solvents such as toluene and paint thinner result in neuropathies, intelligence impairment, changes in cerebellar morphogenesis and atrophy, pregnancy problems and birth defects.⁵

Table 4. Comparison of pathologic findings according to weeks in the study groups.

	1st week	3rd week	4th week	5th week		p
	X±SD	X±SD	X±SD	X±SD	KW	
Inflammation	1.8±0.83	0.83±0.40	1.2±0.44	1.2±0.44	6.39	>0.05
Exocytosis	1.6±0.89	0.5±0.83	1.2±0.44	1.2±0.44	5.99	>0.05
Metaplasia	1.4±1.14	1.16±0.40	2±0.70	1.4±0.54	3.95	>0.05
Budding	1±1.22	0.66±0.51	1.4±1.14	1.2±0.44	2.49	>0.05
Stratification	1±0.70	0.66±0.81	1.2±0.83	0.6±0.89	2.08	>0.05
Villiform changes	0	0.2±0.44	0.6±0.89	2.2±0.83	12.85	<0.01

The exact mechanism by which the thinner causes neuropathy is unknown. But it is believed that thinner, destroys a great amount of fat that makes up the myelin and causes atrophy by demyelination.⁶

In a study performed by Carabez et al (1998), thinner inhalation affected the rats' CNS by increasing the distance of intersynaptic space and then causing the diminution of the efficacy of the neurotransmitter molecules at the postsynaptic membrane.⁵

In our study, during the thinner inhalation, we observed slowing of the movements, difficulty in walking, somnolance and increase in the depth and the number of respiration of the rats. We also observed an increase in defecation number of the rats. Throughout the following days of the study, there was an increase in the aggressive behaviors of the rats. Those were the findings of the CNS intoxication.

In addition, as a result of thinner inhalation, damages of the liver, kidneys, hematopoetic and cardiovascular systems were reported.^{1,3,7,8}

Clinically, volatile substance abuse is characterized by a rapid onset of intoxication and a rapid recovery. Soon after the inhalation of volatile substances; euphoria, disinhibition, feeling of invulnerability may be observed. Later on, vertigo, visual and auditory hallucinations may follow the relaxation, fatigue and the sleepiness. In higher doses, changes in perception, frightening hallucinations, tinnitus, ataxia and confusion may be seen. In volatile substance abuse, tolerance may develop, but no sign of the withdrawal syndrome are observed.^{1,3}

The most serious acute effect of volatile substance intoxication is sudden death. Four direct reasons can be recognized related to sudden death with volatile substance abuse: vagal inhibiton, anoxia, respiratory depression and cardiac arrhythmias. Indirect effects such as aspiration of vomitus, asphyxia associated with the use of a plastic bag and trauma during ataxia may also cause death.^{1,3,9}

Al-Alousi (1989) pointed out that the most frequently encountered feature is the pulmonary oedema in cases of volatile substance abuse. Other respiratory findings are chronic inflammation, intraalveolar hemorrhages with focal pulmonary collapse and laryngeal oedema.¹⁰

Helquist et al (1983) examined nasal mucosae of the ten spray painters. The histopathological examinations showed that, in the exposed group, the cilia and the areas of normal respiratory epithelium disappeared and in all cases the nasal mucosae were lined with squamous epithelium which were sometimes metaplastic. Two cases displayed a mild epithelial dysplasia. The epithelium-stroma junction projected into the underlying stroma in some areas (budding). Histopathologically no evidence of a precancerous lesion was observed. However, none in the exposed group had a normal mucosa.¹¹

In our study, there were no cilia loss, mucous gland hypertrophy and basement membrane thickening histopathologically in the thinner inhaled rats. Inflammation and exocytosis were observed in all rats especially in the first group. A lower degree of inflammation was also observed in some rats in the control group. It is thought to be the result of the laboratory-originated infections. But the difference between the control and study groups were not statistically significant ($p>0.05$). Also the evaluations made among the study groups revealed no statistical differences, although the changes in the first group were observed to be more prominent (Table 3).

Focal metaplastic areas, stratifications and projections into the underlying stroma (budding) were present in all study groups. These findings became prominent especially in the fourth week. But the differences between the study groups were not statistically significant ($p>0.05$). By the third week, hyperplasia of the epithelium followed by villiform projections were detected. The villiform changes among the different weeks of the study revealed to be significantly increased in the consecutive weeks. (Table 4).

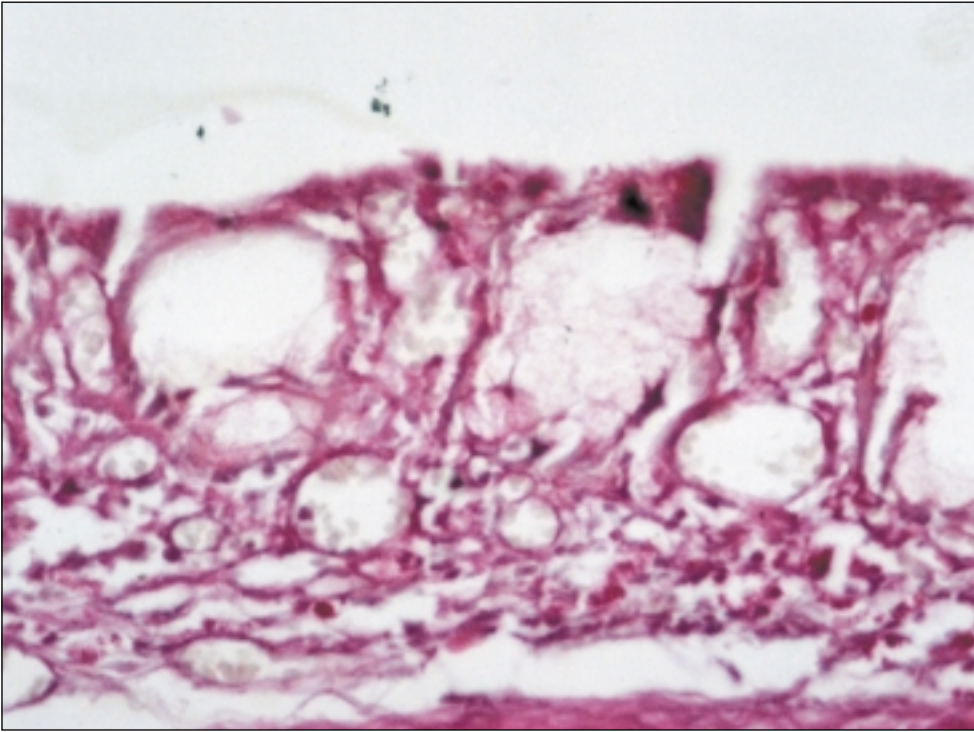


Figure 4. Nasal mucosa of group 3. Minimal inflammation and epithelial villiform projections (HE x40).

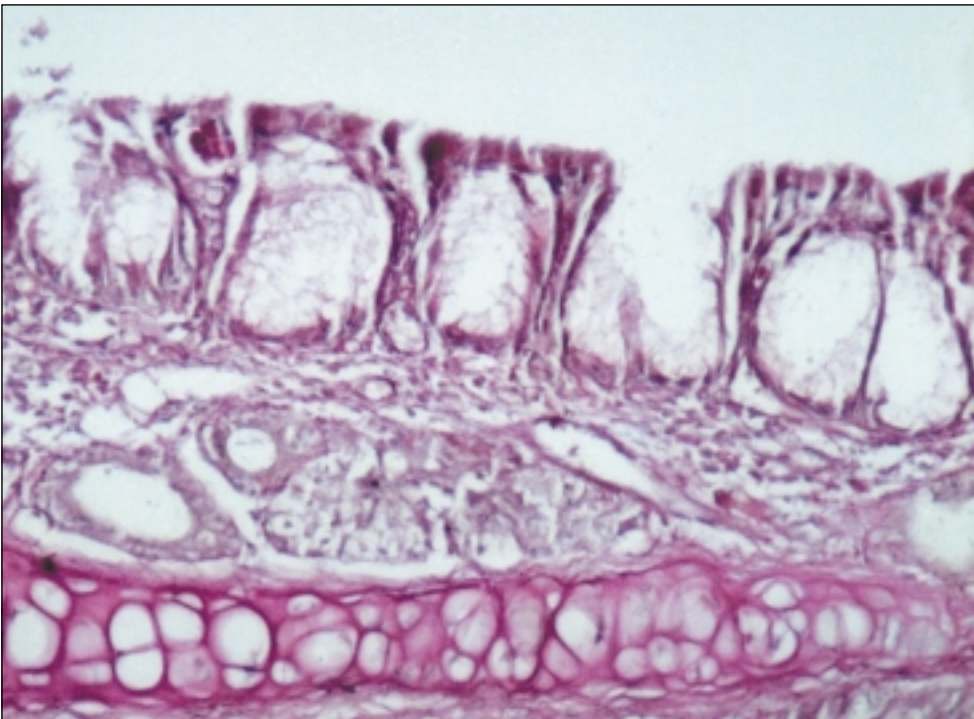


Figure 5. Nasal mucosa of group 4. Prominent villiform changes (HE x40).

Conclusion

Most of the nitrated compounds have shown to be rather powerful carcinogens, and an increased risk for the development of nasal carcinoma in nickel workers had been shown in epidemiological studies. Tarjussen et al (1979), investigated the histopathological changes of the nasal mucosa in nickel workers. They demonstrated that 47% of nickel workers exhibited dysplasia of the nasal mucosa. It is thought that they would progress in invasive nasal tumors.^{11,12}

There is no evidence that substances in the composition of the thinner are carcinogenic alone. Because of the hyperplastic changes that occur in the rat nasal mucosa after thinner inhalation, we think that these substances can be carcinogenic when they are present together. Further investigations should be performed to prove this.

Irritation of the mucous membranes and the skin is another acute but usually less severe effect caused by solvents. The asthmatic conditions associated with the solvent exposure, usually as a result of a non-specific hyperreactivity were reported.¹¹

Toluene diisocyanate (TDI) induced asthma occurs in approximately 10% of workers involved in manufacturing of plastics, foams, adhesives and surface coatings. Inhalation of TDI vapour in the work place induces occupational asthma, rhinitis and nasal irritation. Previous studies have demonstrated that a single TDI exposure is sufficient to produce airway epithelial damage, inflammation and bronchial smooth muscle hyperresponsiveness. This is mediated in part by the release of Substance P (SP) from the sensory nerve fibers at the airway wall. Recent studies suggest that the airway irritants affect the neuropeptide levels in the sensorial neurons. Allergen provocation in the nasal cavity increases SP content resulting in a neurogenic inflammation. It is generally thought that SP release in the nasal cavity mediates or promotes protective responses including mucosal edema, mucous secretion, and inflammatory cell influx. So TDI which is a derivate of thinner causes inflammation in the nasal mucosa.¹³

In our study, inflammation can not be accepted as an effect of thinner because there is no statistically significant differences between control and study groups.

Yamada et al (1993), observed significant retardations in the increase of the body weight of the rats which inhaled thinner twice daily until the disappearance of righting reflex.⁷

Jenkins et al (1970), reported in their study that the mean body weight of 15 rats which inhaled toluene for 8 hours daily, 5 days a week; was increased from 252 gr to 321 gr at the end of the sixth week. But this increase was not statistically significant.¹⁵

In our study, when compared with the control group, the mean body weight of the study group decreased significantly at the end of the fifth week. The evaluations made among the different weeks of the study showed significant decreases in the body weights of the rats especially at the fifth week (Table 1 and 2).

In conclusion, we observed the changes in the nasal mucosa of the rats who inhaled the thinner twice a day until the disappearance of righting reflex in a period of up to 5 weeks. In contrast to the control group, after the first week, metaplasia, budding and stratifications were detected in the study group. Among the study groups, there were no statistically significant differences in these findings. However, villiform changes first appeared in the second group and increased significantly in the following weeks. According to these results, it is obvious that the abuse of volatile substances is very dangerous; further detailed evaluations should be done to demonstrate the damages on the nasal mucosa.

References

1. **Flanagan RJ, Ruprah M, Meredith TJ, Ramsey JD.** An introduction to the clinical toxicology of volatile substances. *Drug Saf* 1990; 5: 359-83.
2. **Ramsey J, Anderson HR, Bloor K, Flanagan RJ.** An introduction to the practice, prevalence and chemical toxicology of volatile substance abuse. *Human Toxicol* 1989; 8: 261-9.
3. **Meadows R, Verghese A.** Medical complications of glue sniffing. *South Med J* 1996; 89: 455-62.

4. **Ulakoğlu EZ, Saygı A, Gümüştaş MK, Zor E, Öztekin İ, Kökoğlu E.** Alterations in superoxide dismutase activities, lipid peroxidation and glutathione levels in thinner inhaled rat lungs: relationship between histopathologic properties. *Pharmacol Res* 1998; 38: 209-14.
5. **Carabez A, Sandoval F, Palma L.** Ultrastructural changes of tissues produced by inhalation of thinner in rats. *Microsc Res Tech* 1998; 40: 56-62.
6. **Barroso-Moguel R, Villeda-Hernandez J.** Experimental neuropathy produced in rats with industrial solvents (thinner). *Arch Invest Med (Mex)* 1989; 20: 53-60.
7. **Yamada K.** Influence of lacquer thinner and some organic solvents on reproductive and accessory reproductive organs in male rat. *Biol Pharm Bull* 1993; 16: 425-7.
8. **Garcia-Estrada J, Rodriguez-Segura A, Garzon P.** Cerebral cortex and body growth development of progeny of rats exposed to thinner and turpentine inhalation. *Gen Pharmacol* 1988; 19: 467-70.
9. **Ellenhorn MJ, Barceloux DG.** Medical toxicology. Amsterdam: Elsevier Science Publishing Company; 1988. p. 940-1001.
10. **al-Alousi LM.** Pathology of volatile substance abuse: a case report and a literature review. *Med Sci Law* 1989; 29: 189-208.
11. **Hellquist H, Irander K, Edling C, Ödkvist AC.** Nasal symptoms and histopathology in a group of spray-painters. *Acta Otolaryngol* 1983; 96: 495-500.
12. **Torjussen W, Solberg LA, Hogetveit AC.** Histopathologic changes of nasal mucosa in nickel workers: a pilot study. *Cancer* 1979; 44: 963-74.
13. **Hunter DD, Satterfield BE, Huang J, Fedan JS, Dey RD.** Toluene diisocyanate enhances substance P in sensory neurons innervating the nasal mucosa. *Am J Respir Crit Care Med* 2000; 161: 543-9.
14. **Marquez-Orozco MC, Marquez-Orozco A, Samano-Bishop A, Lorenzana-Jimenez M, Rodriguez-Carranza R.** Histological and ultrastructural alterations of the testis of rat induced by chronic inhalation of paint thinner. *Proc West Pharmacol Soc* 1983; 26: 81-2.
15. **Jenkins LJ, Jones RA, Siegel J.** Long-term inhalation screening studies of benzene, toluene, o-xylene, and cumene on experimental animals. *Toxicol Appl Pharmacol* 1970; 16: 818-23.

Correspondence: Sema Zer Toros, MD

Department of Otorhinolaryngology & Head and Neck Surgery
Haydarpaşa Numune Hospital, Istanbul, TURKEY
Phone: +90 (216) 414 45 02 / 1745
e-mail: semazertoros@hotmail.com