

OLGU BİLDİRİSİ / CASE REPORT

Large maxillary ameloblastoma: a case report

G.K. Beriat, H. Ezerarslan, Ş. Dağlı, S. Kulaçoğlu

Büyük maksiller ameloblastom: Olgu sunumu

Ameloblastoma, odontojenik kökenli, nadir bir epitelyal tümördür. Ameloblastomaya çoğulukla mandibulada rastlanırken, nadiren maksillada da görülür. Diğer odontojenik ve non-odontojenik çene tümörlerinin semptomlarının ameloblastomla benzer olması nedeni ile ayırıcı tanıda zorluklar ortaya çıkar. Benign bir hastalık gibi düşünülse de hızlıca büyüyebilir ve çevre dokuları invaze edebilir. Maksillada kortikal kemik dokusunun daha ince olması nedeni ile maksillada yer alan lezyonlar mandibulada bulunanlara göre daha invazivdir ve daha çok yayılma eğilimindedir. Bu olgu sunumunda periorbital dokular, infratemporal fossa, paranasal sinüsler, sert damak ve premaksiller subkutanöz dokuya yayılım gösteren, tedavisinde genel anestezi altında midfasiyel degloving ameliyatı uygulanan, büyük maksiller ameloblastom vakası sunulmuştur.

Anahtar Sözcükler: Büyük ameloblastom, maksilla, odontojenik tümör.

Abstract

Ameloblastoma is a rare epithelial tumor of odontogenic origin. Ameloblastoma is mostly encountered in the mandible but it is rarely seen in maxilla. It may reveal difficulties in distinguishing other odontogenic and non-odontogenic jaw tumours because it can mimic symptoms and diagnosis of these. Although it is considered as a benign disease it can grow very rapidly and infiltrate the surrounding tissues. The lesions in the maxilla tend to be more extensive and invasive than those in the mandible because of the lesser amount of dense cortical bone. This case report presents one of the large maxillary ameloblastomas with an extension to periorbital tissues, infratemporal fossa, paranasal sinuses, hard palate and premaxillary subcutaneous tissue.

Key Words: Large ameloblastoma, maxilla, odontogenic tumor.

Türk Otolarengoloji Arşivi, 2009; 47(2): 93-98

Turk Arch Otolaryngol, 2009; 47(2): 93-98

Güçlü Kaan Beriat, MD; Hande Ezerarslan, MD
Department of Otolaryngology, Ankara Ufuk University Hospital, Ankara
Şafak Dağlı, MD
Department of Otolaryngology, Mustafa Kemal University Hospital, Hatay
Sezer Kulaçoğlu, MD
First Pathology Department, Ankara Numune Research and Training Hospital, Ankara

Introduction

Ameloblastoma is considered a low grade malignant basaloid tumor with a variable range of histopathologic patterns, clinical forms and behavior.¹

Ameloblastoma is an unusual epithelial tumor, which accounts for only about 1% of all oral tumors of odontogenic origin.² Approximately 80% of ameloblastomas occur in the mandible and 70% of them arise in the molar region and ascending

ramus, 20% in the premolar and 10% in the incisor region.³ It is much rarer in the maxilla and represent about 20 % of all ameloblastomas. 50% of these maxillary tumors are found in the molar region, 30% in the maxillary antrum, and the rest at other sites, including less than 2% in the anterior maxilla.²

The lesion may clinically evident is as early as the first decade or as late as the seventh.² The earliest case being reported belongs to a 2 year old child, but it is most common in the fourth decade.^{4,5}

Histologically most ameloblastomas fall within two major morphologic configurations the follicular and plexiform types. Combinations and variations of these two types, as well as other subtypes are found even within the same lesion. The follicular type consist of small to large odontogenic epithelial nests and variously shaped and sized ameloblastomatous islands. The plexiform type consist of interlacing strands of narrow or wide odontogenic epithelial trabeculae. Both types have a columnar or cuboidal outer epithelial cell layer bordering the connecting tissue stroma and enclosing the inner epithelial cells. The characteristic histologic signatures of the ameloblastoma are the orientation of the epithelial cell nuclei, which are positioned away from the basement membrane, and the frequent vesicular appearance of the outer cell cytoplasm next to the basement membrane. In addition, the inner epithelial cells of follicles are more or less loosely arranged as in a stellate reticulum, imitating the enamel organ architecture. Not infrequently the strandular narrow configuration of the plexiform lesion has neither the outer epithelial cell nuclear orientation nor the appearance of inner cell stellate reticulum. A variety of subtypes are built around the basic morphologic characteristics. Compression of the stellate reticulum into a squamoid mass with squamous metaplasia and keratinization produces the acantomatous subtype. The inner follicular and outer follicular cells may assume a basal cell appearance throughout the

lesion causing a striking resemblance to basal cell carcinoma in which instance basal cell type is noted. In the same manner granular cell types spindle cell types recognized.

Case Report

A 66-year-old woman was admitted to the outpatient clinic of otorhinolaryngology with a swelling of the palate and alveolar process on the left side of the upper jaw.

The patient had suffered from left periorbital pain and a mass swelling the left palate and protruding the gingivobuccal mucosa. Nasal obstruction and purulent nasal discharge lasted more than 5 months. The patient did not suffer from a bleeding nose.

Physical examination revealed a semisolid mass under the cheek. The left nasal cavity was totally obstructed by the mass which prevented endoscopic examination. The right nasal cavity was normal. Nasopharynx was free of tumor. The patient was edentulous. The history did not reveal any relation with the teeth extraction. The teeth of the patient were extracted 8 years before than the appearance of the mass, due to carious.

Plain sinus x-rays demonstrated an opacification of the right maxillary sinus with loss of the bony walls. A computed tomography scan of the sinuses revealed a diffuse expansion of the left maxillary sinus, left ethmoidal and sphenoidal sinuses and left intranasal cavity with abnormal soft tissue density and ethmoidal destruction of the left infraorbital, hard palatal, lateral nasal and posterior maxillary walls (Figures 1a and b). Although the orbital fat was attacked by the tumor, the eye movements were within normal range.

An incisional biopsy was performed under local anesthesia and the microscopic examination of the biopsy specimens were prepared for hematoxylin-eosin staining and revealed as ameloblastoma (Figure 2a).

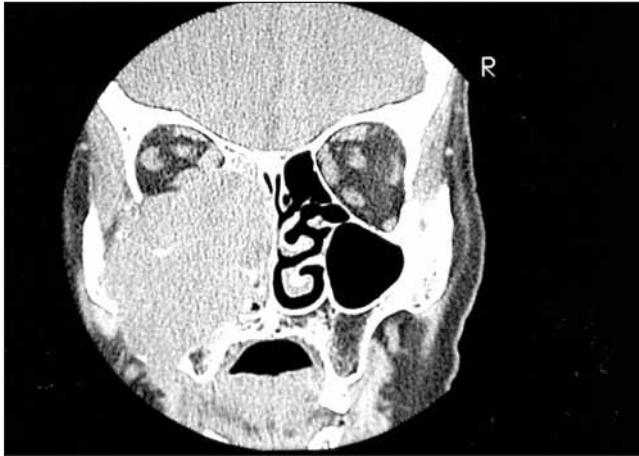

Figure 1a. Coronal CT revealed a solid mass invading the orbital soft tissue, intranasal cavity, cheek and palatal region.

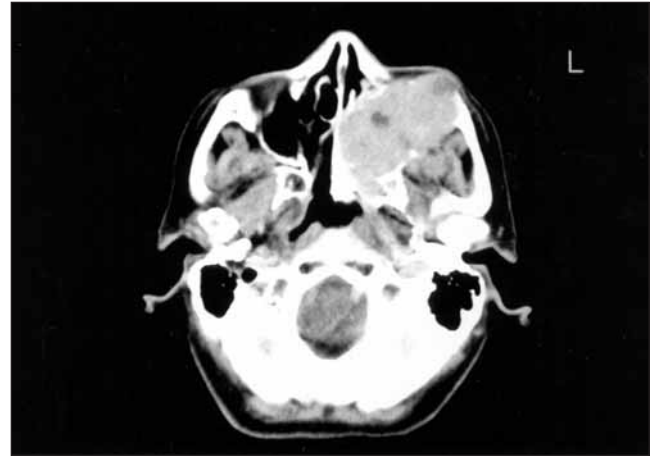


Figure 1b. Axial CT showed that the mass had cystic areas with an extension to premaxillary skin.

The patient was operated on under general anesthesia. We performed to mid-facial degloving technique. The tumor sized 10X11X9 was removed en-block preserving facial skin, hard palatal mucosa and the eye with a large intranasal defect. Postoperative histologic examination revealed plexiform ameloblastoma (Figure 2b). The postoperative period, 5 years follow up of the patient revealed no recurrence and complications.

Discussion

Ameloblastoma is a benign neoplasm that may be locally invasive and strong tendency to recur.^{1,6} It may show periods of dormancy and rapid expansion. The pain is rarely a presenting symptom unless the lesion causes root resorption. The first sign is usually a deformity of the upper jaw or an ill fitting upper dental prosthesis due to expansion of the alveolar process. When the tumor has a medial or anterior localization in the maxilla there may be nasal discharge or repeated episodes of epistaxis.⁷ It arises from the epithelial rests of Serres or Malassez, the enamel organ, the epithelial lining of dentigerous cysts, or the basal layer of the oral mucosal

epithelium. This tumor is composed of entirely soft tissue. Approximately 17% of ameloblastomas have been associated with an impacted tooth or dentigerous cyst. Although this phenomenon is frequently observed in individuals below the age of 30, it may occur in the fourth decade or older with an equal gender predilection.³ This finding leads some to propose that microscopic examination of all dentigerous cysts or impacted tooth follicles is warranted.³ It typically presents as a gradually expanding, painless swelling.

The most frequent site of origin of ameloblastomas is the molar region of the mandibula. In the maxilla the third molar region is the most commonly affected site.² Such tumors may extend into the nose, orbit, maxillary sinus or base of the skull.

Ameloblastomas have been classified as peripheral and central with subgroups.

Various types of ameloblastomas exhibit differences in behavior that necessitate various methods of treatment.³ Over 96% of the cases of this lesion are central (intraosseous) and the peripheral variant is rare.⁸

The modalities of treatment of an ameloblastoma range from a conservative approach such as cure-

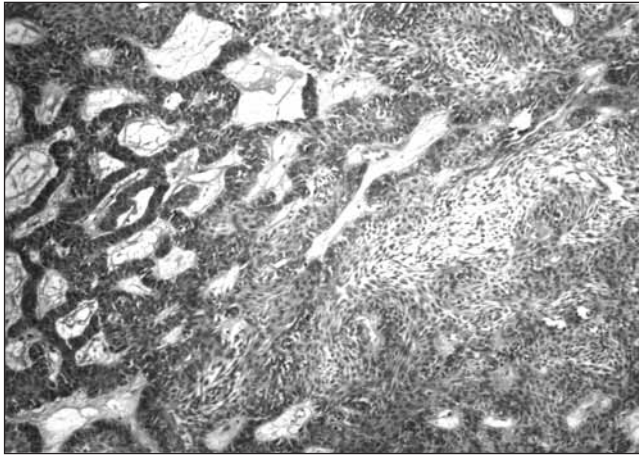


Figure 2a. Anastomosing islands and cords of epithelial cells in a fibrous stroma and cystic spaces are lined by a layer of low columnar or cubic cells (left). The cords were composed of double layer epithelial islands also showing palisading (middle). Central portion of these islands were composed of loosely arranged spindle shaped cells, suggesting stellate reticulum (**Hematoxylin-eosin staining x40**).

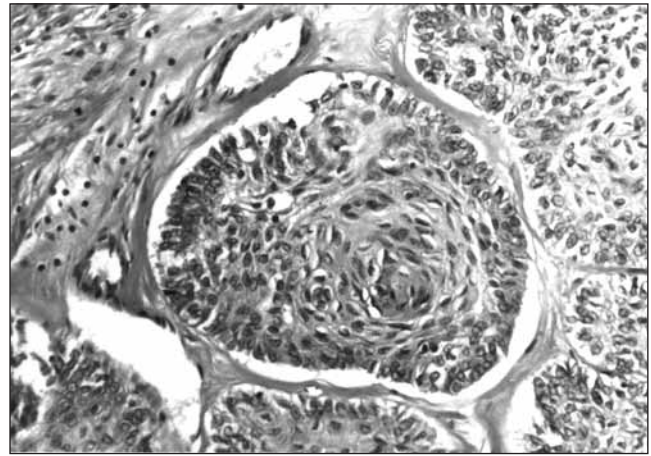


Figure 2b. Some of the islands showed squamous metaplasia within stellate reticulum. This is typical for acanthomatous growth pattern in ameloblastomas (**Hematoxylin-eosin staining x100**).

tage, chemical cautery, electrocautery, cryosurgery, radiation therapy to a radical excision or combination of these modalities.^{3,7} Surgical treatment of these tumors is controversial. The method of treatment depends on a number of variables, including the size, location and duration of the tumor, the physical condition of the patient, and the surgical experience.^{7,9} Conservative therapy has a role to play in the management of the solid or multicystic ameloblastoma due to the possibility of cure of this neoplasm. Unfortunately, the lack of long-term and scientific follow-up patients can not justify 'conservative' therapy.¹⁰

Maxillary ameloblastomas may behave in a clinically malignant fashion with direct extension beyond the site of origin. They have a slower progressive growth that may permit enucleation with complete removal a partial or complete maxillary resection.⁷

Since the maxilla has considerably less dense cortical bone than the mandible and is so closely related with the nasal cavity, paranasal sinuses,

orbital contents, pharyngeal tissues, and vital structures at the base of the skull, the maxillary ameloblastomas have a greater propensity for extension. Therefore the maxillary ameloblastomas recur more often than the mandibular ameloblastomas. Maxillary recurrences could be salvaged by a more extensive partial or total maxillectomy.¹¹

The radiographic image of ameloblastoma is evident but not pathognomonic.¹ Radiographically the ameloblastoma presents an unilocular or multilocular radiolucent appearance, lesional edge may be distinct or indistinct in a several different forms and shapes. Radiographically lesions may be unilocular, multilocular, well circumscribed, but clinically the tumor is infiltrative and not encapsulated.

Ameloblastoma presents several clinical form and histologic type, frequently combinations of this form and type occur. The major intrabony clinical forms are unicystic, multicystic and solid. The peripheral ameloblastoma is extraosseous soft tissue form of the lesion found in the gingiva and

mucosa. A large unicystic lesion displayed elements of plexiform, granular cell, follicular and acanthomatous types. A unicystic lesion may arise as an ameloblastoma de novo or form secondarily in an odontogenic keratocyst or dentigerous cyst. The lesion may remain small, become large or even develop into a multicystic form. Occasionally small satellite cysts, separated from the main lesion, may be undetected clinically and radiographically. Small or large unicystic lesions that contain with or without impact teeth are usually identified radiographically as dentigerous cyst or odontogenic keratocyst. Identification of the lesion as ameloblastoma may occur if a biopsy sample is taken or after excision and preparation of histologic sections. Occasionally a unicystic lesion particularly of the plexiform type is misdiagnosed as an inflamed cyst with hyperplastic epithelial lining. The mural ameloblastoma another name for a unicystic lesion is found in children, teenagers and young adults.

Solid and multicystic lesions may have similar origin in a field of neoplastic chain. Small foci of ameloblastoma spread out in a three dimensional manner as the foci become masses and retain a solid form or make micro or macrocystic lined by ameloblastic epithelium. Intraosseous ameloblastoma grows slowly by invasion of medullary spaces and resorption of cancellous and cortical bone. Peripheral ameloblastoma is presumed to originate from residual or displaced odontogenic tissue in the gingiva or mucosal surface overlying the alveolar process. The peripheral tumor has a basaloid pattern primarily but frequently is mixed with follicular and acanthomatous elements and in the absence of other subtypes appears identical to basal cell carcinoma.

Treatment must be guided by consideration of the growth characteristics of the various physical forms, the anatomic site of occurrence, the clinical extent and size of the tumor and histologic assessment of the specific lesions. Patient's physical status

and capacity are other important factors for selection of surgical approach and method.

The goal of treatment is the total removal of the tumor by whatever surgical procedure. We know that, postoperative long term and careful follow up is very important because of high recurrence rate of these tumors. Suggested post treatment follow up time is 15 to 20 years.

The first procedure should be planned to be definitive and offer the best opportunity for cure, with the least psychological distress imposed on the patient.

Usually, separate the histologic behavior of tumor, curettage and enucleation are inadequate surgical therapy methods. Especially for solid and multicystic intraosseous lesions following recurrence rates known is 55% to 100%. This rate for intraosseous unicystic lesions is 18% to 25%. Another important point is difficult to follow healing by radiographic examination of a lesion that has been treated by curettage, since recurrence may appear radiographically similar to formation of bone.

Cancellous bone is easily infiltrated and resorbed by the tumor, dense cortical bone is a temporary barrier for spread of tumor as well as the symphysis of mandibula. Resorption of cortical bone by the tumor permits growth into the periosteum if periosteum is penetrated surrounding muscle and soft tissue is infiltrated.

Surgical safe margin of involved bone is approximately 2 cm for solid and multicystic lesions and 1 to 1.5 cm for unicystic and peripheral lesions.

We choose the facial degloving technique for this case, because this technique allows good exposure of the nasal cavities and bones of the middle third of face. With appropriate dissection, retraction and bony removal, the nasal septum, maxillary and ethmoid sinus, pterygopalatine area and infratemporal fossa can all be explored.

This technic's other advantages are allows additional modification and extension, successful control of a wide variety of disease, no external scarring, good patient tolerance. The only disadvantage is the occasional occurrence of nasal vestibular stenosis. This complication can prevent with frequent dressings.

A long term follow-up is important because of the tendency for the tumor cells to lie beyond the supposed margins of the tumor especially in plexiform unicystic and multicystic or solid types.³ A close follow in warranted in these tumors, because recurrences after 30 years following surgery has been reported.³

Conclusion

Ameloblastoma are rarely malignant, slowly growing, locally invasive and prone to recur. The inability of the pathological diagnosis and inadequate surgical therapy cause problems of management in these tumors.

An unusually large maxillary ameloblastoma with an extension to orbita, paranasal sinuses, premaxillary region was presented, which was removed by

mid-facial degloving technique and tumor was en-block resection and curetage without any peroperative and postoperative complications.

References

1. **Raymond J, Fonseca DMD.** Oral and Maxillofacial Surgery, Vol. 5. Philadelphia: W.B. Saunders Company; 2000. p. 334-58.
2. **Frank JS, Melvin S, Anthony JM.** Maxillary ameloblastoma: case report. *Am J Otolaryngol* 1991; 12: 20-5.
3. **Peter EL, Arden KH.** Otolaryngology Head and Neck Surgery. 2nd ed. St. Louis, Missouri: Mosby Year Book; 1992. p. 1430-3.
4. **Tsaknis PJ, Nelson JF.** The maxillary ameloblastoma: an analysis of 24 cases. *Oral Surg* 1980; 38: 336-42.
5. **Batsakis JG, McClatchey KD.** Ameloblastoma of the maxilla and peripheral ameloblastomas. *Ann Oto Rhinol Laryngol* 1983; 92: 532-3.
6. **Porter J, Miller R, Stratigos GT.** Ameloblastoma of the maxilla: report of a case. *J Oral Surg* 1977; 44: 34-8.
7. **Biörklund A, Elnor A, Snorraddottir M.** Ameloblastoma of the maxilla. Report of three cases. *J Laryngol Otol* 1979; 93: 1105-13.
8. **Takahashi K, Yoshino T, Hashimoto S.** Unusually large cystic adenomatoid odontogenic tumour of the maxilla: case report. *Int J Oral Maxillofac Surg* 2001; 30: 173-5.
9. **Hollows P, Fasanmade A, Hayter JP.** Ameloblastoma - A diagnostic problem. *Br Dent J* 2000; 188: 243-4.
10. **Carlson ER, Marx RE.** The ameloblastoma: primary, curative surgical management. *J Oral Maxillofac Surg* 2006; 64: 484-94.
11. **Kim SG, Jang HS.** Ameloblastoma: a clinical, radiographic, and histopathologic analysis of 71 cases. *Oral Surg Oral Med Oral Pathol Oral Radiol Endod* 2001; 91: 649-53.

Conflict of interest statement:

No conflicts declared.

Correspondence: Hande Ezerarslan, MD

Department of Otolaryngology,
Ankara Ufuk University Hospital
Balgat 06520 ANKARA
Phone: +90 312 468 66 71
Fax: +90 312 284 77 86
e-mail: handearslan5@yahoo.com