

OLGU BİLDİRİSİ / CASE REPORT

Eagle's syndrome: pre, per and postoperative views of a case

F. Kasapoğlu, L. Erişen

Eagle sendromu: Bir olgunun pre, per ve postoperatif görüntüleri

Bu makalede Eagle sendromu tanısı olan 36 yaşındaki bir bayan hastanın radyolojik görüntülemeleri, peroperatif ve postoperatif görüntüleri sunulmuştur. Bu sendromun tanısı ve ayırıcı tanısı, bilgisayarlı tomografinin üç boyutlu rekonstrüksiyonu ve dijital fotoğraf gibi teknolojik gelişmeler sayesinde oldukça kolaylaşmıştır.

Anahtar Sözcükler: Yüz ağrısı, Eagle sendromu, uzamış stiloid çıkıntı, tomografi, üç-boyutlu.

Abstract

In this case report we present the preoperative radiological images, peroperative and postoperative views of a 36-years-old female Eagle's syndrome patient. The diagnosis and differential diagnosis of this syndrome have become quite easy after technological advances, such as three dimensional computed tomographic reconstruction and digital imaging.

Key Words: Facial pain, Eagle's syndrome, elongated styloid process, tomography, three-dimensional.

Türk Otolarengoloji Arşivi, 2009; 47(3): 147-150

Turk Arch Otolaryngol, 2009; 47(3): 147-150

Introduction

Eagle's syndrome (ES), is a complex of symptoms, the etiology of which is not yet fully enlightened, caused by the elongation of the styloid process or ossification of the stylohyoid ligament.¹⁻³ The ES might be unilateral or bilateral. Although rarely encountered in clinical practice, it might also lead to complaints frequently observed in the otorhinolaryngology practice, such as headache, persistent sore throat and facial pain, dysphagia, globus pharyngeus, tinnitus, pain reflecting in the ear, pain during tongue movements, changes in voice and feeling of hypersalivation.¹⁻⁵ In addition to

Fikret Kasapoğlu, MD; Levent Erişen, MD
Department of Otolaryngology and Head&Neck Surgery, Faculty of Medicine,
Uludağ University, Bursa

the history, palpation of the tonsillar region and neck, and radiological examination are also useful in the diagnosis.

The syndrome was first defined by Eagle in 1937. The average length of the styloid process in adults is 2.5-3 cm, and this is a thin, cylindrical formation belonging to the temporal bone, located anterior to the stylomastoid foramen, extending laterally towards the tonsillar fossa.^{1,3} A styloid process longer than 3 cm is accepted as pathological.⁶ Symptoms are due to the pressure exerted on the neighboring glossopharyngeal nerve by an elongated or broken styloid process, or a calcified stylohyoid ligament.^{1,3}

We present the preoperative, peroperative and postoperative images of a 36-year-old female patient in this study, since these views were typical of ES. We also aimed to emphasize the technological advances in obtaining these images.

Case Report

A 36 years-old female patient was admitted with a complaint of sore throat, which was particularly located on the left side, and aggravated by neck movements. She also had continuous globus feeling, and intermittent left earache. The patient had not been satisfied with the medical treatments prescribed previously, and had neither complaints of dyspnea or dysphagia, nor a history of trauma, dental problems or tonsillectomy.

On physical examination, extreme tenderness was found on palpation of the hyoid bone and left palatine tonsil. Besides, the styloid processes were both palpable in the left tonsillar fossa. X-rays demonstrated elongation of the left styloid process. The final diagnosis was made by three-dimensional reconstruction of computed tomographic examination scans (Figure 1).

During surgery; elongated styloid process was clearly visualized on the left tonsillar fossa after ton-

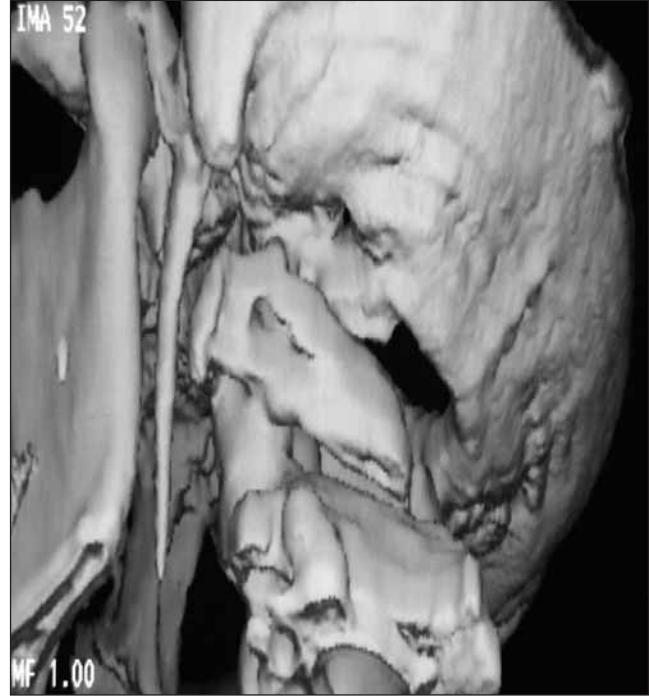

Figure 1. Three-dimensional reconstruction of computed tomography showing left elongated styloid process.

sillectomy (Figure 2A), and the patient was treated with partial resection of the styloid process (Figure 2B). Postoperative period was uneventful and her complaints resolved completely.

Discussion

Eagle's syndrome (ES) is a complex of symptoms with unknown etiology, which manifests itself with elongation of the styloid process or ossification of the stylohyoid ligament. ES might be unilateral or bilateral. Although it is rare, it causes many complaints seen frequently in otorhinolaryngology practice, such as headache, persistent throat and facial pain, dysphagia, globus pharyngeus, tinnitus, otalgia, painful tongue movements, voice changes and hypersalivation.^{1,3} Palpation of the neck and the palatine tonsils, and radiological imaging, in addition to the patient's history are helpful in the diagnosis.

Though 4% of the general population is thought to have an elongated styloid process, only a small proportion of this group (4-10%) is symptomatic.^{1,3,7,8} No data exists on the relationship between the length of the styloid process and the severity of the symptoms.^{3,8} There are different styloid process patterns of calcifications, angulations and other morphometric characteristics which are described in the literature.⁹⁻¹¹

A normal styloid process is non-palpable, therefore an elongated process may be easily diagnosed by its palpation in the tonsillar fossa. Symptoms may be aggravated or triggered with the palpation of the tip of styloid process. Also, relief of the symptoms with injection of a local anesthetic agent into the tonsillar fossa is highly suggestive of the diagnosis.^{1,3}

Radiographic imaging is frequently helpful in supporting the diagnosis if the clinical evaluation is doubtful. Besides direct X-rays and CT scans, three-dimensional reconstruction techniques, which have been developed recently, clearly show the dimensions of the styloid process.^{3,4,9,10,12-15} Besides, it is easier to explain the problem in detail to the patients, with three-dimensional CT.¹²

However, it should be noted that the radiological findings must always be evaluated together with the history and physical examination of the patient, since not every elongated styloid process leads to ES. The final step in the diagnosis is peroperative evaluation by (as in our case, Figure 2A) palpating or visualization of the elongated styloid process in the tonsillar fossa after tonsillectomy.

Since ES can mimic several diseases, its differential diagnosis includes some neuralgic syndromes, particularly the glossopharyngeal, trigeminal and sphenopalatine neuralgias. Also, oromandibular pathologies, unerupted molar teeth, temporomandibular joint disorders and irritating prosthetic teeth should be considered. Besides, tumors and inflammatory conditions of the oropharynx, hypopharynx and parapharyngeal regions should be kept in mind.^{1,16-20}

Treatment of ES can be both surgical and non-surgical. Non-steroid anti-inflammatory agents and steroid injections are non-surgical treatments.^{3,4} Transoral and transcervical approaches may be used for surgical therapy. The transoral approach, though having advantages such as easy access to pathology

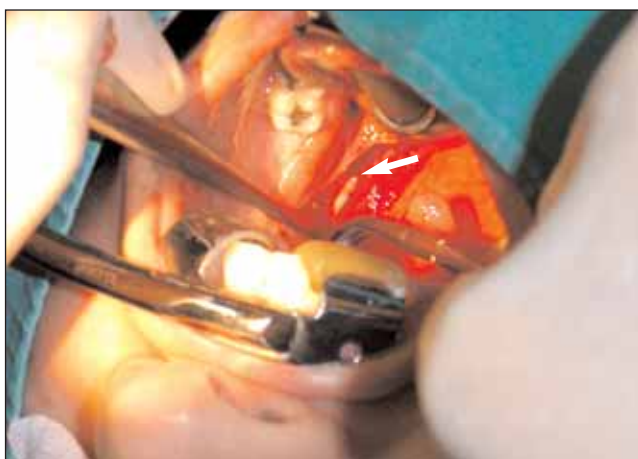


Figure 2A. Elongated styloid process (arrow) is per-operatively seen in the left tonsillar fossa. [Color figure can be viewed in the online issue, which is available at www.turkarchotolaryngol.org]

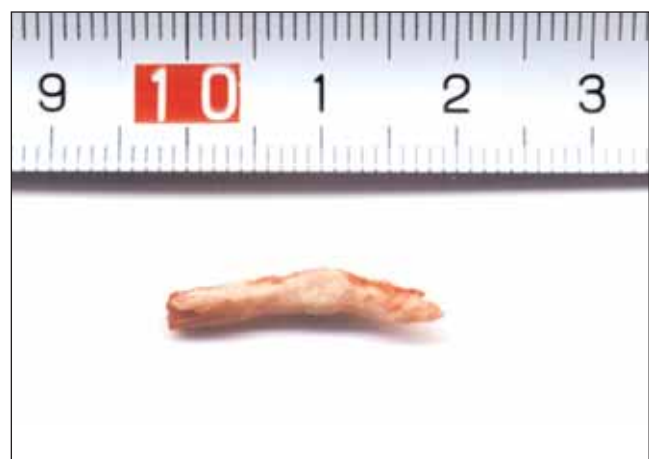

Figure 2B. Partially resected styloid process. [Color figure can be viewed in the online issue, which is available at www.turkarchotolaryngol.org]

and better cosmetic outcome, has been reported to have a few disadvantages such as narrow operative field and risk of deep neck infection.^{12,21}

Because our case's picture obtained peroperatively by a digital camera is demonstrative, we have decided to present this case and wished to stress that this pathology, which had been difficult to visualize in the past, can easily be documented today, preoperatively by three-dimensional reconstruction of computed tomography and peroperatively by a digital camera picture.

Conclusion

The pre, per and postoperative imaging and documentation of the Eagle's syndrome, which originates from an area that is difficult to access clinically and whose diagnosis and differential diagnosis remains doubtful at times, has become quite easy after the technological advances, such as three dimensional CT reconstruction, and digital imaging.

References

1. **Rechtweg JS, Wax MK.** Eagle's syndrome: a review. *Am J Otolaryngol* 1998; 19: 316-21.
2. **Philipp K, Barnes EL, Carrau RL.** Eagle syndrome produced by a granular cell tumor. *Arch Otolaryngol Head Neck Surg* 2001; 127: 1499-501.
3. **Murtagh RD, Caracciolo JT, Fernandez G.** CT findings associated with Eagle syndrome. *AJNR Am J Neuroradiol* 2001; 22: 1401-2.
4. **Baugh RF, Stocks RM.** Eagle's syndrome: a reappraisal. *Ear Nose Throat J* 1993; 72: 341-4.
5. **Strauss M, Zohar Y, Laurian N.** Elongated styloid process syndrome: intraoral versus external approach for styloid surgery. *Laryngoscope* 1985; 95: 976-9.

6. **Keur JJ, Campbell JP, McCarthy JF, Ralph WJ.** The clinical significance of the elongated styloid process. *Oral Surg Oral Med Oral Pathol* 1986; 61: 399-404.
7. **İlgüy M, İlgüy D, Güler N, Bayırlı G.** Incidence of the type and calcification patterns in patients with elongated styloid process. *J Int Med Res* 2005; 33: 96-102.
8. **Erol B.** Radiological assessment of elongated styloid process and ossified stylohyoid ligament. *J Marmara Univ Dent Fac* 1996; 2: 554-6.
9. **Savranlar A, Uzun L, Uğur MB, Özer T.** Three-dimensional CT of Eagle's syndrome. *Diagn Interv Radiol* 2005; 11: 206-9.
10. **Başhekim CÇ, Mutlu H, Güngör A, et al.** Evaluation of styloid process by three-dimensional computed tomography. *Eur Radiol* 2005; 15: 134-9.
11. **Kursoğlu P, Ünalın F, Erdem T.** Radiological evaluation of the styloid process in young adults resident in Turkey's Yeditepe University faculty of dentistry. *Oral Surg Oral Med Oral Pathol Oral Radiol Endod* 2005; 100: 491-4.
12. **Beder E, Özgürsoy OB, Karataylı Özgürsoy S, Anadolu Y.** Three-dimensional computed tomography and surgical treatment for Eagle's syndrome. *Ear Nose Throat J* 2006; 85: 443-5.
13. **Gözil R, Yener N, Çalgüner E, Araç M, Tunç E, Bahçelioğlu M.** Morphological characteristics of styloid process evaluated by computerized axial tomography. *Ann Anat* 2001; 183: 527-35.
14. **Beder E, Özgürsoy OB, Karataylı Özgürsoy S.** Current diagnosis and transoral surgical treatment of Eagle's syndrome. *J Oral Maxillofac Surg* 2005; 63: 1742-5.
15. **Lee S, Hillel A.** Three-dimensional computed tomography imaging of Eagle's syndrome. *Am J Otolaryngol* 2004; 25: 109.
16. **Ünlü Z, Tarhan S, Gündüz K, Göktan C.** Relationship between ossification of the stylohyoid ligament and enthesopathy: a comparative study. *Clin Exp Rheumatol* 2002; 20: 661-7.
17. **Genç S, Kürkçüoğlu SS, Tuncel U, Babademez MA, Acar B, Karabulut H.** Eagle's syndrome: a case presentation. *Agri* 2007; 19: 43-7.
18. **Yetişer S, Gerek M, Özkaptan Y.** Elongated styloid process: diagnostic problems related to symptomatology. *Cranio* 1997; 15: 236-41.
19. **Aral İL, Karaca İ, Güngör N.** Eagle's syndrome masquerading as pain of dental origin. Case report. *Aust Dent J* 1997; 42: 18-9.
20. **Orhan KS, Güldiken Y, Ural Hİ, Çakmak A.** Elongated styloid process (Eagle's syndrome): literature review and a case report. *Agri* 2005; 17: 23-5.
21. **Chase DC, Zarmen A, Bigelow WC, McCoy JM.** Eagle's syndrome: a comparison of intraoral versus extraoral surgical approaches. *Oral Surg Oral Med Oral Pathol* 1986; 62: 625-9.

Conflict of interest statement:

No conflicts declared.

Correspondence: Fikret Kasapoğlu, MD

Department of Otolaryngology and Head&Neck Surgery,
Faculty of Medicine, Uludağ University,
Görükle 16069 BURSA
Phone: +90 224 295 26 45
Fax: +90 224 442 80 91
e-mail: fkasapoglu@uludag.edu.tr