

# Laser Photocoagulation of Tongue Hemangioma: Case Report

## *Dil Hemanjiyomunun Lazer Fotokoagülasyonu: Olgu Sunumu*

Case Report  
Olgu Sunumu

Berke Özücer, Sabri Baki Eren, Remzi Doğan, Selahattin Tuğrul, Orhan Özturan

Department of Otorhinolaryngology and Head and Neck Surgery, Bezmialem Vakıf University, İstanbul, Turkey

### Abstract

This report describes two cases of tongue hemangioma and shows the effectiveness of photocoagulation with diode laser. A thirty-five year-old female patient with a tongue hemangioma measuring 20x30 mm was referred. The lesion had been present for 15 months and the patient reported a gradual enlargement with dental trauma. A forty-three year-old female patient had a tongue hemangioma measuring 21x25 mm. The lesion was located on the right lateral side of her tongue and had caused minor discomfort with dental trauma for the previous 8 months. Lesions were surgically photocoagulated with a diode laser applied through a glass microscope slide. The procedures lasted 15 minutes

and the patients were discharged on the first postoperative day. Minimal swelling and crusty scarring occurred during the first postoperative week. After one month, the operative sites healed without any residual scarring. Patient satisfaction was achieved with minimal morbidity. Lower morbidity, minimal patient discomfort and satisfactory aesthetic results are favorable for the patients. Laser photocoagulation is promising as the treatment of choice for such lesions.

**Key Words:** Hemangioma, tongue, laser, diode laser, photocoagulation

### Özet

İki dilde hemanjiyom vakasının ve diyod lazer fotokoagülasyonu ile etkin tedavisinin sonuçlarının sunumu. Otuz beş yaşında kadın hasta dilinde 20x30 mm'lik mor renkli lezyonla başvurdu. Anamnezde 15 aydır lezyonun dental travmayla büyüme hikayesi mevcuttu. Kırk beş yaşında kadın hasta dilinin sağ lateralinde 21x25 mm'lik lezyonla başvurdu. Lezyon 8 aydır dental travmayla minor rahatsızlık vermektedir. Lezyonlar mikroskop lam üzerinden uygulanan diyod lazer ile fotokoagüle edildi. Operasyonlar kanamasız ve süre olarak yaklaşık 15 dakikaydı; her iki hasta da ilk postoperatif günde taburcu

edildi. İlk postoperatif haftada minimal ödem ve cerrahi sahada kabuklanma oluştu. Bir aylık takip sonunda cerrahi sahanın rezidü skar görüntüsü olmadan iyileştiği görüldü. Hasta memnuniyeti minimal morbiditeyle sağlandı. Düşük morbidite, yüksek hayat kalitesi ve kozmetik açıdan tatmin edici hasta memnuniyeti hastalar açısından tercih sebebiydi. Lazer fotokoagülasyonu bu tip lezyonların tedavisinde tercih edilebilecek bir tedavi yöntemidir.

**Anahtar Kelimeler:** Hemanjiyom, dil, lazer, diyod lazer, fotokoagülasyon

### Introduction

Hemangiomas are benign vascular proliferations consisting of numerous capillary structures and are especially common on the tongue, lips and gums (1). A number of treatment modalities have been proposed for the treatment of hemangiomas including steroids, surgical resection and laser (2, 3).

There are several types of lasers used in the literature for treatment of vascular lesions of the head and neck region: Carbon dioxide (CO<sub>2</sub>) lasers and potassium titanyl phosphate (KTP) lasers are used for ablation of subglottic hemangiomas (4-6). The neodymium-doped yttrium aluminum garnet (Nd:YAG) laser provides a bloodless field and complete healing of the hypopharynx without stenosis or scar formation. The safety and value of CO<sub>2</sub> and Nd:YAG lasers in endoscopic laryngeal microsurgery is well documented for the treatment of glottic cancer.

A new laser has been introduced for oral soft tissue procedures; the diode laser is useful because of the high absorption by chromophores, such as hemoglobin, melanin, and collagen. The diode laser ability to cut while also performing coagulation and hemostasis and a higher tissue ablation capacity are advantages which make diode laser the treatment of choice for such lesions (7). Use of diode laser has been recently reported in the literature for vascular lesions of head and neck (8, 9).

The purpose of this study was to report two clinical cases of tongue hemangioma located on the tongue and to show the effectiveness of photocoagulation with the diode laser. In these cases, the diode laser



33<sup>rd</sup> National Otorhinolaryngology and Head and Neck Surgery Congress 26.10.2011-30.10.2011 Antalya Susesi Hotel, Antalya, Turkey

33. Ulusal Kulak Burun Boğaz, Baş ve Boyun Cerrahisi Kongresi 26.10.2011-30.10.2011 Antalya Susesi Otel, Antalya, Türkiye

**Address for Correspondence/Yazışma Adresi:**  
Berke Özücer, Department of Otorhinolaryngology and Head and Neck Surgery, Bezmialem Vakıf University, 34093 Fatih, İstanbul, Turkey  
Phone: +90 530 963 59 39  
E-mail: berkeozucer@gmail.com  
**Received Date/Geliş Tarihi:** 17.12.2012  
**Accepted Date/Kabul Tarihi:** 10.01.2013

© Copyright 2013 by Official Journal of the Turkish Society of Otorhinolaryngology and Head and Neck Surgery Available online at [www.turkarchotolaryngol.net](http://www.turkarchotolaryngol.net)  
© Telif Hakkı 2013 Türk Kulak Burun Boğaz ve Baş Boyun Cerrahisi Derneği Makale metnine [www.turkarchotolaryngol.net](http://www.turkarchotolaryngol.net) web sayfasından ulaşılabilir.  
doi:10.5152/tao.2013.15

was pressed against the lesion with a microscope slide between, which provided a diffuse transfer of the energy to deeper tissues without causing necrosis at the superficial endothelial layer. Informed patient consent was obtained for publication of treatment photographs.

## Case Reports

### Clinical Case 1

The patient was a 35-year-old female who was referred to our clinic with the chief complaint of a lesion located anteriorly on the left half of her tongue. The lesion had been present for 15 months and the patient reported gradual enlargement and episodes of bleeding with dental trauma. Patient did not report any problems regarding respiration or swallowing but had minor problems with clarity in word articulation. The patient's history was negative for alcohol or tobacco use. Physical examination of the patient revealed a bluish colored painless lesion, sensitive to palpation measuring 20x30 mm which was clinically diagnosed as an hemangioma (Figure 1a). The physical examination of the head and neck region was unremarkable apart from this lesion.

### Clinical Case 2

A forty-three year-old female patient was referred to our clinic with the chief complaint of a gradually enlarging bluish colored 21x25 mm lesion sensitive to palpation. The lesion was located on the right lateral side of her tongue and had been present for 8 months. It was diagnosed as an hemangioma (Figure 2a). The patient's history was negative for alcohol or tobacco use. Head and neck examination was normal. The patient reported minor discomfort with dental trauma and episodes of non-significant bleeding that ceased spontaneously.

Diode laser photocoagulation was planned and laboratory carried out for blood coagulogram preoperatively. Photos were taken for comparison with post-operative results and the lesion was measured to the nearest millimeter. Patients were provided with information about the procedure and

written informed consents were obtained prior to the procedure.

Lesions were surgically photocoagulated with the Intermedic Multidiode SLP™ S30 Gallium Arsenide P diode laser (Lower Saxony, Germany). The selected instrument was configured to 940-1000 nanometers wavelength; pulse and pause were both configured to 300 ms, power was adjusted to 12 Watts and emission pulse of the device was 5 ms to CW. The laser was applied through a glass microscope slide which was inserted in-between in order to avoid direct contact with the lesion (Figure 1b, 2b). When whitening and coagulation of the tissue was observed, laser application was ceased. Although the laser was applied with a 2 mm-width cable, each local photocoagulation affected a 5x5 mm region. Therefore, the laser was applied evenly in a widespread fashion to prevent excess focused energy transfer and tissue necrosis.

The procedure was performed in the supine position, intravenous antibiotics (1000 mg cefazoline) and dexamethasone (10 mg) was administered 1 hour prior to surgery. Adequate laser protection was used by the OR staff and the patient. Operation duration was approximately 15 minutes for both cases and there was no bleeding. 1 mg/kg prednisolone was administered postoperatively for prevention of swelling and securing the airway. Patients were admitted for overnight airway observation. Oral intake was tolerated well within 4 hours. Patients were discharged from hospital on the first postoperative day with non-steroid antiinflammatory drugs and 0.12% gluconate chlorhexidine suspension mouthwash. Additional corticosteroid pomade was prescribed for local effect.

Both patients were seen in the first postoperative week: minimal swelling was present at the operative site, and crusty scarring was present (Figure 1c, 2c). Patients reported that these symptoms lasted until flaking and peeling of the crusty layer in approximately two weeks following surgery. The second visit around the

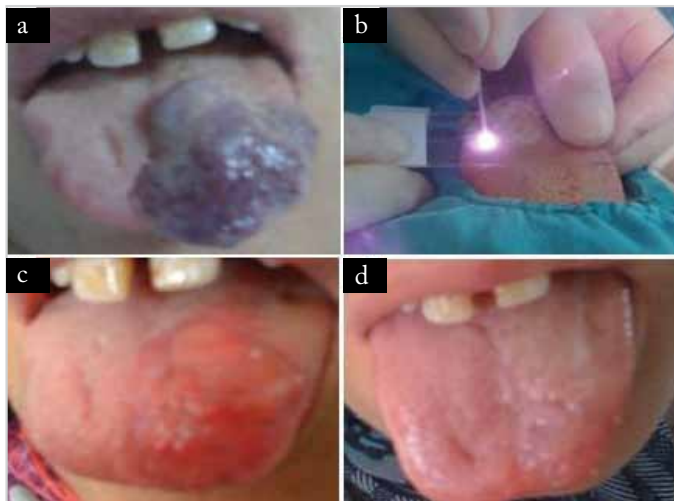


Figure 1. Case 1 (a) preoperative (b) intraoperative (c) postoperative tenth day (d) postoperative first month

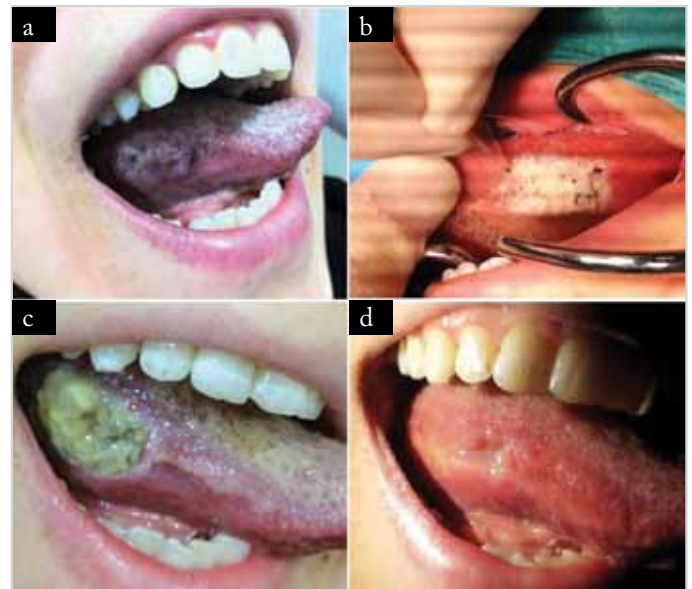

Figure 2. Case 2 (a) preoperative (b) intraoperative (c) postoperative tenth day (d) postoperative first month

first postoperative month revealed a totally healed operative site without any residual scarring (Figure 1d, 2d). For both cases, patient satisfaction was obtained with minimal morbidity.

## Discussion

Treatment of hemangiomas can be performed with many alternative methods including corticosteroid therapy, intralesional sclerosing agents, embolization and surgery. Conventional surgery can lead to hemorrhage; complete resection of an hemangioma raises concerns such as postoperative morbidity and aesthetic appearance. Absence of intraoperative bleeding, shorter operation duration and lower morbidity are advantages of laser photocoagulation over conventional surgery. In this case, maximal quality of life was achieved in a minimally invasive fashion. Although general anesthesia was used in this case, local anesthesia can be considered in suitable patients; a similar operation was carried out and published in which a tongue hemangioma was ablated via laser under analgesedation (10).

Hemangiomas of the oropharynx and oral cavity are more deeply situated. Diode laser is suitable for oral soft tissue procedures because of their ability to cut while also performing coagulation and hemostasis and a higher tissue ablation capacity compared to other lasers (7). Direct application of the laser causes a local "point by point" effect, but insertion of a microscope slide in-between enables an evenly and diffusely distributed effect to the deeper tongue tissue.

Postoperative pain and discomfort were minimal and manageable with non-steroid antiinflammatory drugs. Postoperative feeding was possible within 5 hours following surgery, the patient was mouth-fed fluids with a drinking straw directed to the posterior oropharynx and discharged from hospital on the same day of the surgery.

## Conclusion

Laser photocoagulation is an effective method for treatment of oral hemangiomas. Lower morbidity, minimal patient discomfort and satisfactory aesthetic results are favorable for patients. Laser photocoagulation is promising as the treatment of choice for such lesions.

## Conflict of Interest

No conflict of interest was declared by the authors.

**Peer-review:** Externally peer-reviewed.

## Author Contributions

Concept - A.N.M., S.B.E.; Design - A.N.M., B.Ö.; Supervision - O.Ö.; Literature Review - B.Ö.; Writer - B.Ö., A.N.M., R.D.; Critical Review - O.Ö., S.T.

## Çıkar Çatışması

Yazarlar herhangi bir çıkar çatışması bildirmemişlerdir.

**Hakem değerlendirmesi:** Dış bağımsız.

## Yazar Katkıları

Fikir - A.N.M., S.B.E.; Tasarım - A.N.M., B.Ö.; Denetleme - O.Ö.; Literatür taraması - B.Ö.; Yazıyı yazan - B.Ö., A.N.M., R.D.; Eleştirel İnceleme - O.Ö., S.T.

## References

1. Sun ZJ, Zhang L, Zhang WF, Alsharif MJ, Chen XM, Zhao YF. Epithelioid hemangioma in the oral mucosa: a clinicopathological study of seven cases and review of the literature. *Oral Oncol* 2006; 42: 441-7. [\[CrossRef\]](#)
2. Buckmiller LM, Richter GT, Suen JY. Diagnosis and management of hemangiomas and vascular malformations of the head and neck. *Oral Dis* 2010; 16: 405-18. [\[CrossRef\]](#)
3. Prasetyono TO, Djoenaedi I. Efficacy of intralesional steroid injection in head and neck hemangioma: a systematic review. *Ann Plast Surg* 2011; 66: 98-106. [\[CrossRef\]](#)
4. Simpson GT, Healy GB, McGill T, Strong MS. Benign tumors and lesions of the larynx in children. Surgical excision by CO2 laser. *Ann Otol Rhinol Laryngol* 1979; 88: 479-85.
5. Healy GB, Fearon B, French R, McGill T. Treatment of subglottic hemangioma with the carbon dioxide laser. *Laryngoscope* 1980; 90: 809-13. [\[CrossRef\]](#)
6. Kacker THE, April M, Ward RF. Use of potassium titanyl phosphate (KTP) laser in management of subglottic hemangiomas. *Int J Pediatr Otorhinolaryngol* 2001; 59: 15-21. [\[CrossRef\]](#)
7. Fornaini C, Rocca JP, Bertrand MF, Merigo E, Nammour S, Ves-covi P. Nd:YAG and diode laser in the surgical management of soft tissues related to orthodontic treatment. *Photomed Laser Surg* 2007; 25: 381-92. [\[CrossRef\]](#)
8. Desiate A, Cantore S, Tullo D, Profeta G, Grassi FR, Ballini A. 980 nm diode lasers in oral and facial practice: current state of the science and art. *Int J Med Sci* 2009; 6: 358-64. [\[CrossRef\]](#)
9. Genovese WJ, dos Santos MT, Faloppa F, de Souza Merli LA. The use of surgical diode laser in oral hemangioma: a case report. *Photomed Laser Surg* 2010; 28: 147-51. [\[CrossRef\]](#)
10. Atkins JH, Mandel JE, Mirza N. Laser ablation of a large tongue hemangioma with remifentanyl analgesedation in the ORL endoscopy suite. *ORL J Otorhinolaryngol Relat Spec* 2011; 73: 166-9. [\[CrossRef\]](#)