

The Management, Current Treatment Modalities and Reconstruction Techniques for Lip Cancer

Review

Gökçe Tanyeri¹, Görkem Eskiizmir²¹Clinic of Otolaryngology - Head and Neck Surgery, Yerköy State Hospital, Yozgat, Turkey²Department of Otolaryngology - Head and Neck Surgery, Faculty of Medicine, Celal Bayar University, Manisa, Turkey

Abstract

The lips are important anatomic structures which have vital and social functions such as eating, drinking, phonation, speaking, kissing and expressing emotions. Squamous cell carcinoma is the most common histopathological type of lip cancer. Sun exposure, smoking, and chronic irritation have an important role in the etiopathogenesis. Lip cancers constitute a serious health problem and their treatment requires a multidisciplinary approach. The operability status of patients, comorbid disease and patient expectations, tumor stage, location,

size, depth and characteristics should be carefully evaluated while planning the treatment of these cancers. The purpose of this article is to present contemporary treatment modalities in cancers of the lip, tumor staging and treatment planning, analysis of lip defects related to surgery, major principles and techniques of lip reconstruction.

Key Words: Lip cancer, squamous cell carcinoma, basal cell carcinoma, lip defects, reconstruction

Introduction

The lip is defined by the Turkish Language Association as: “the curved structures that are located just at the upper and lower edges of the mouth in order to cover the teeth”. Both upper and lower lips are found on the bottom one-third of the face forming a single complex anatomical structure. The lips have very important social functions such as speaking, articulation, phonation, laughing and kissing; in addition to their vital functions such as eating, drinking, and sucking. The development of cancer on the lips which are important functionally and aesthetically, constitute a serious health problem.

Incidence and Etiology

Lip cancers are generally epithelial tumors that are generally located at the vermilion border (1). They are the second most common cancers of the head and neck region and constitute almost 2,06% of all cancers (2). It was reported that the incidence of lip cancer in US is 1,8/100.000 and 3600 new cases are expected every year (3). According to a retrospective study that depends on the U.S. National Cancer Database, the frequency of lip cancer was reported as 3.5% between 1990-1994, 2.7% between 1995-1999, and 1.9% between 2000-2004. In addition, the frequency of lip cancer was estimated as 7.7/100.000 in Australia (4).

most common histopathological type on lip cancer is squamous cell carcinoma (SCC). Although the most common (>95%) histopathological type on the lower lip is SCC, basal cell carcinoma (BCC) is seen relatively more frequently on the upper lip (6, 7). The reason of increased frequency of SCC on the lower lip can be explained by the increased sun exposure of the lower lip (5). Since lips do not have a protective pigment layer, they are more vulnerable to solar damage. The lip cancer on the lower lip develops especially from the damaged regions of the vermilion or premalignant lesions. The male/female ratio is approximately 6/1 among the patients with lip cancer, and there is a significant increase in its frequency especially at the 6th and 7th decades (8-10). Unfortunately, recent studies demonstrated that there is a significant increase in the incidence of lip cancer among females and at relatively younger population.

Many environmental and genetic factors play role in the etiology of lip cancer. The major risk factors that are already shown to have direct relationship with the development of lip cancer are: sunlight, rural life, chemical carcinogens, ionizing radiation, cigarette, occupation, genetics, race, socio-economic status, viral infection, and immune deficiency. The etiologic factors that have less effect on the development of lip cancer are alcohol consumption, poor oral hygiene, tuberculosis and syphilis (11, 12).

Lip cancers are mainly divided into three groups, according to their locations: upper lip, lower lip and commissure. These cancers have different characteristics and clinical presentations (5). Of all the lip cancers, 80% of them develop on the lower lip, 7-15% of them develop on the upper lip and 5-7% of them develop at commissure (6). The

Even though the carcinogenesis of lip cancer might be related to only one factor, current concept advocates a complex and combined relationship between etiologic factors. The most important etiopathological factor of lip cancers is ultraviolet

Address for Correspondence:
 Görkem Eskiizmir, Department of Otolaryngology
 - Head and Neck Surgery Faculty of Medicine, Celal
 Bayar University, Manisa, Turkey
Phone: +90 535 327 85 52
E-mail: geskiizmir@hotmail.com
Received Date: 01.02.2014
Accepted Date: 14.02.2014

© Copyright 2014 by Official Journal of the Turkish
 Society of Otorhinolaryngology and Head and
 Neck Surgery Available online at
 www.turkarchotolaryngol.net
 DOI:10.5152/tao.2014.488

radiation (UVR) which is generally related to the sunlight exposure. The most significant evidences supporting this opinion are the higher incidence of lip cancer among men and people working under sun; and the low incidence among people who apply lipstick and protectives regularly. In addition, important relationships between cigarette/tobacco and oral cavity cancers have been demonstrated. The smoking habits can affect the location of cancer; while pipe smoking and non-inhaling smoking are the potential risk factors for lip cancers; chewing tobacco and tobacco-like plants (such as bettel-nut in India, Maraşotu in Turkey) and reverse smoking, defined as smoking a cigarette from the lit end, are mainly known as the potential risk factors for oral cavity cancers. Smoking that cause exposure to several carcinogens such as benzopyrene and nitrosamine, is accused as the major reason for the increased incidence of lip cancers in females.

Tumor histopathology and characteristics

The most common histopathological types of lip cancers are SCC and BCC.

Squamous Cell Carcinoma

Squamous cell carcinoma is a malignant neoplasm that is originated from epidermal keratinocytes and in which cells show squamous differentiation in varying degrees. Squamous cell carcinoma is composed of fibers and membranes of squamous epithelial cells derived from epidermis reaching dermis. There is an eosinophilic cytoplasm and most often a vesicular nucleus; permanent intercellular bridges and central keratinizations in varying degrees (13, 14). The cells of chronic inflammation and sometimes eosinophils can be observed at the periphery of tumor samples. Cytokeratin and epithelial membrane antigens are positive in squamous cell carcinoma (15). The histopathological examination is subjectively categorized as: well, moderately and poorly differentiated. The presence of perineural lymphocytes is an important finding for perineural invasion.

Ultraviolet light is an important cause of squamous cell carcinoma in people with fair skin. Intensive UVR exposure during childhood and adolescence is a risk factor increasing the potential of SCC development (13-15). The mutations of p53 gene are the most common genetic abnormalities found in Actinic Cheilitis (AC) and SCC, and these lead to the formation of resistance in tumor cells against apoptosis (16). The histopathological spectrum of squamous cell carcinoma begins with AC. Histopathologically, the difference between AC, *in situ* SCC and invasive SCC is defined as: involvement that takes a place at the small part of epidermis for AC, totally for *in situ* SCC and invasive SCC extends across or below the basal membrane of the epidermis. Squamous cell carcinoma typically occurs as a flesh-colored papule, nodule or plaque on the sun damaged skin. It is generally hyperkeratotic, together with central necrosis and hemorrhagic area. The biological behavior of SCC is determined by its location, size, depth and histopathological differentiation (17). While well-differentiated SCC shows nearly total keratinization, poorly differentiated SCCs are composed of fusiform cells that can sometimes be defined exactly only by some special

histopathological markers. Poorly differentiated tumors have a poor prognosis, together with an increase in the frequency of recurrence and metastasis. Squamous cell carcinoma has many histopathological subtypes: (i) acantholytic SCC (adenoid, adenocanthoma), (ii) spindle cell carcinoma, (iii) verrucous carcinoma, (iv) pseudovascular SCC, (v) adenosquamous cell carcinoma, (vi) hyaline SCC, (vii) papillary SCC, (viii) desmoplastic SCC, and (ix) pigmented SCC.

Basal Cell Carcinoma

Basal cell carcinoma is a malignant tumor that is considered to develop from basal epidermal cells or the external root sheath of the hair follicle. These tumors are characterized by locally aggressive behavior; they almost always grow slowly (a 1-2 cm increase in diameter of a tumor generally takes a few years) and have a low metastasis potential (<0.1%) (18). Sun exposure is a significant factor in the development of BCC. It is suggested that the carcinogenesis of BCC is especially triggered by the early exposure (before the age of 20 years) to UVR.(19, 20). It is known that UVR causing the development of BCC has significant effects on DNA damage and immunosuppression (20, 21). Histopathologically, BCC has several subtypes: (i) nodular, (ii) superficial, (iii) infiltrative, (iv) morpheaform, (v) metatypic, (vi) micronodular and (vii) basosquamous types. However, complex histopathological findings may be observed in almost 40% of BCCs (18, 20).

Diagnostic Techniques

Lip cancer can generally be detected early, because it is visible due to its anatomical location. The most common symptoms are non-healing wound on the lip, recurrent incrustation, bleeding and pain. The history and physical examination are very important for the diagnosis of lip cancer. The final diagnosis is established by histopathological examination. The medical histories of these cases should be investigated in detail in terms of the age and occupation of the patient, the duration of lesion, the presence of being exposed to risk factors and its frequency, medication used for lesion, concurrent diseases, and previous medical treatment and surgical interventions. A detailed head and neck examination is mandatory; thus, the presence of multifocal diseases, lymphatic metastases and secondary primary lesions can be detected. Firstly, the location, size and type of the lesion must be identified through inspection, and then, the induration of the tumor and its relation with surrounding tissues for bone and/or soft tissue invasion must be evaluated by palpation. Concurrent premalign lesions must be investigated carefully during this examination. The premalign lesions with potential to transform into SCC are: AC, erythroplakia, leukoplakia, Bowen's disease, lichen planus (especially nodular form), keratoacanthoma, and xeroderma pigmentosum. Palpational examination of the neck (particularly submental, submandibular and jugular chain) must be performed carefully for the possible presence of lymphadenopathy. The location, consistency, and size of the lymph nodes that are evaluated by palpation and whether they are painful and moving or not must be noted (13).

Incisional or excisional biopsy must be conducted for the final diagnosis of lip cancer. Considering possible further surgical in-

tervention, this biopsy procedure must be designed in a way that its limits can be expanded and it is important not to take the samples from necrotic area. Moreover, histopathological diagnosis with fine-needle aspiration biopsy can be performed in patients who have suspicious lymph node metastasis (22). In addition to the histopathological evaluation of the tumor, radiological evaluations are required for the detection of the depth of invasion and regional and distant metastasis especially in patients with advanced stage tumors. Consequently, all examinations and inspections provide critical findings about the stage of cancer, size and depth of tumor, its characteristics and histopathological features. Thus, the most appropriate alternatives can be determined for the treatment and surgical planning of lip cancer and reconstruction of the deformity.

Grading and Staging

Broders classified SCCs based on microscopic grading, according to which tumors are grouped into 4 grades (23):

- Grade I: More than 75% of the lesion is well-differentiated (Well-differentiated)
- Grade II: 50-75% of the lesion is well-differentiated (Moderately differentiated)
- Grade III: 25-50% of the lesion is well-differentiated (Low-differentiated)
- Grade IV: Less than 25% of the lesion is well-differentiated (Poorly differentiated/anaplastic)

More than 85% of lip cancers are Grade I and Grade II tumors, only 2% are Grade IV. Nuclear atypia is apparent in Grade IV tumors and slight keratinization is detected in small areas. In poorly- and low-differentiated cancers, the risk for metastasis is higher and the prognosis is poorer.

Clinical staging must be performed for all patients with lip cancer. The TNM system is highly important for deciding on treatment planning, identifying prognosis and comparing results. T is used for tumor size (Figure 1); N is for the presence, size, direction and number of lymph nodes; and M is for the presence of distant metastasis.

TNM staging based on the guidelines of *American Joint Committee on Cancer* (AJCC, 2010) for lip cancers is presented in Table 1 (24).

Treatment Methods

The target of the treatment for lip cancers are (i) local and regional eradication of tumor, (ii) maintenance or restoration of lip functions, and (iii) obtaining an aesthetically acceptable outcome (25). Each case and tumor is unique. Patients should be informed about the characteristic, stage, treatment and prognosis of the tumor. The general condition of patient, his/her comorbid diseases, extent of disease and reconstruction alternatives, and the patient's expectations should be taken into consideration, while determining the treatment method.

The treatment methods available for lip cancers include surgery, radiotherapy, cryotherapy, topical chemotherapy, electrodesicca-

tion/curettage and photodynamic therapy. Surgery is the first choice due to the higher morbidity rate of radiotherapy compared to surgical treatment for early stage lip cancers, although the outcomes of radiotherapy and surgical treatment are similar (5). Photodynamic therapy is a method preferred for the prevention of scar formation however, long term follow-up is of utmost important. Cryotherapy is an inexpensive method; however, the healing rate is low. In addition, immunomodulating drugs (for example, imiquimod) are also recommended for superficial BCC successfully (26). Moreover, various treatment methods, such as topical 5-fluorourasil, intralesional interferon and laser, are also applied.

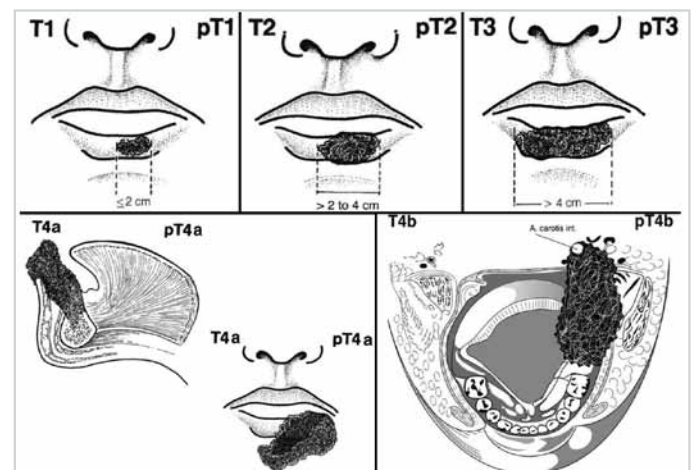


Figure 1. Schematic demonstration of T staging

Table 1. TNM Staging based on the guidelines of American Joint Committee on Cancer (AJCC, 2010) for lip cancers

T	TX	Non-identified primary tumour
	T0	No evidence of primary tumour
	Tis	Carcinoma in situ
	T1	The largest size of tumor, ≤ 2 cm
	T2	The largest size of tumor, 2-4 cm
	T3	The largest size of tumor, > 4 cm
	T4a	Tumor involvement in cortical bone, inferior alveolar nerve, floor of the mouth and face skin (nose and chin skin)
	T4b	Tumor involvement in masticator space, pterygoid plates or skull base and/or invasion of internal carotid artery
N	Nx	Non-identified regional lymph nodes
	N0	No metastasis of regional lymph node
	N1	Single ipsilateral lymph node, the largest size of which is ≤ 3 cm
	N2a	Single ipsilateral lymph node, the largest size of which is > 3 cm - < 6 cm
	N2b	Multiple ipsilateral lymph nodes, the largest size of which is < 6 cm
	N2c	Bilateral or contralateral lymph nodes, the largest size of which is < 6 cm
M	N3	Lymph node or nodes, the largest size of which is > 6 cm
	M0	Absence of remote metastasis
	M1	Presence of remote metastasis

Surgery

The aim of surgery for lip cancers is the excision of the tumor with surrounding normal tissue completely and to provide both functional and cosmetic reconstruction (5). A surgical margin of 5-10 mm is generally recommended in order to have the total excision of tumor (5, 27). The rate of cure after excision is 95% for BCC and 92% for SCC and it is closely related to the location, size and form of the tumor (28). Early stage lesions (approximately 1.5 cm) must be excised with an excision of one third of the lower lip with surgical margin of 5-7 mm. The frequency of local recurrence depends directly on the size of the lesion. The frequency of recurrence is 12-15% for <2 cm lesions and 55-70% for >4 cm lesions (29). A study in which 72 cases with early-stage lower lip cancer (94.4% T1) were evaluated, demonstrated that only two patients (2.8%) had recurrence after a resection of tumor with a surgical margin of 3 mm (30). They advocated that a surgical margin of 3 mm is sufficient for early-stage lower lip SCCs, if the surgical margins are checked with frozen sections.

Radiotherapy

Radiotherapy can also be used as curative or adjuvant treatment modality for lip cancer. It is preferred for patients who are inoperable or who do not want to have surgery. In addition, palliative radiotherapy may play a role for the improvement of quality of life in patients with advanced stage and who do not have curative treatment modality (13, 18, 21). The outcomes of surgery and radiotherapy are similar in small lesions. The radiotherapy is contraindicated in these clinical situations: cases who have recurrence after curative radiotherapy, cases with mandibular invasion, cases with suspected mandibular or mental nerve involvement, and younger patients (29). The major disadvantages of radiotherapy include high recurrence rates, difficulty in controlling surgical limits, frequent poor cosmetic outcomes, and long-term treatment and risk for development of additional skin cancer due to radiation (31, 32). Furthermore, De Visscher et al. compared surgery and radiotherapy for early stage lower lip cancers and reported that regional recurrence rate increased as tumor diameter increased in patients who underwent radiotherapy (33). The main advantages of surgical treatment compared to radiotherapy are as follows:

- In advanced and larger lesions, healing rate is high.
- The application and rehabilitation are more rapid.
- It determines the surgical margins and histopathological degree of all tumour.
- It provides better functional and cosmetic outcomes.
- The radiotherapy related early and late complications are avoided (5, 27, 34).

Brachytherapy

Brachytherapy is a specific technique of radiotherapy where a radioactive source is placed in natural gaps in contact with the tumor and/or inside the tumor itself. The primary advantage of this treatment method is the maintenance of aesthetic and functional features of the lip (35). In lip cancers, a radioactive source is placed into the tumor with special applicators. These radioactive materials allow delivery of high tumor dose. "Low

dose rate" is the most commonly used radioactive source, but "high dose rate" has also been used recently. It is assumed to be the most efficient radiotherapy method for the treatment of lip cancer. Since the radiation volume is low, it is safer than external RT. One of the other advantages of this technique is the rate of radiation dose is high enough at the tumor; however relatively low at its periphery; (35). The main limitation of this technique is the requirement of an experienced team.

Brachytherapy can be used as treatment modality in 90% of T1 and T2 lip cancers (35). Therefore, brachytherapy is performed as the first treatment modality in several medical centers of Europe. Brachytherapy is contraindicated in cases with gross tissue loss and tumors with bone involvement.

Intraarterial Chemotherapy

Intraarterial chemotherapy is a treatment modality which is mainly based on the delivery of single or combined chemotherapeutics directly to the tumor region via arteries. This modality minimizes the side effects, such as nausea and vomiting, and provides maximum benefit from anticancer features of drugs. In a study conducted with 6 cases that had Stage I and II lower lip cancer, a superselective facial artery infusion of chemotherapeutics mitomycin C and peplomycin were administered successfully to all patients (36). Moreover, in a case series by Wu et al. (37), continuous methotrexate infusion (200-500 mg) was performed to seven patients with stage I and II lower lip cancer. Both studies reported complete response and no recurrence or complication during 5-year and 28-month follow-up periods, respectively. These studies emphasized the safety and efficiency of intraarterial infusion chemotherapy for the treatment of T1 and T2 lower lip cancers.

The management of neck in lip cancers: The rate of lymph node metastases in lip cancers range from 3% to 29% (38). This rate is below 10% in early-stage tumors. However, in advanced stages (in relation with tumor size and depth), the rate of neck lymph node metastases and cancer-induced mortality increase gradually (27,39). The rate of neck metastases are related to the size and depth of the primary tumor and, T value. The rate of metastases were reported as 0-15% for T1 tumors, 11-35% for T2 tumors, and 63% for T3 tumors (40). The first and most common metastasis in neck are detected at submandibular and submental regions (41).

Neck dissection is always a must in cases who have an obvious cervical lymph node metastasis. Since the rate of cervical lymph node metastases in early-stage lower lip cancers is low, close and regular follow-up is recommended instead of prophylactic neck dissection (Figure 2). On the other hand, it is necessary to perform prophylactic neck dissection to patients with T3-T4 tumors, commissure lesions, and recurrent cases, even though lymph node metastasis is not detected clinically. The recommended technique of neck dissection in these clinical situations is selective (supraomohyoid) neck dissection. Some physicians suggest ipsilateral or bilateral suprahyoid neck dissection with primary tumor resection in early-stage lip cancers. The aim of

this view is not to provide cure and prophylaxis, but to determine whether there is a metastasis to the first lymph node station or not. A neck dissection is applied afterwards to patients who have a positive lymph node in the specimen of suprahyoid neck dissection. Recently, sentinel lymph node dissection has been recommended as an alternative surgical modality and successful outcomes have been reported (42,43). Preauricular lymph nodes should be examined carefully in patients with upper lip SCC and superficial parotidectomy should be performed to patients with positive lymph nodes.

Surgical Anatomy

The upper lip is embryologically formed by the prominence of the medial nasal process with two maxillary processes and the intermaxillary segment. The lower lip develops by the prominence of two mandibular processes. Depending on this concept, the upper lip is divided into three aesthetic subunits, and the lower lip itself is accepted to be an aesthetic unit.

In the cross-sectional examination of the lower and upper lip, it is seen that they are composed of four layers: (i) skin, (ii) subcutaneous tissue, (iii) muscle and (iv) oral mucosa. The skin covers the outer part of lips which is the intersection point of the oral mucosa and outer skin, excluding vermilion. The vermilion is the modified shape of mucosa, lacking sweat glands, hair follicles and salivary glands. The vermilion is the most distinctive characteristic of the lip and it is composed of specialized stratified squamous epithelium. Subcutaneous tissue, orbicularis oris muscle and mucosa covering the oral cavity are located just below the vermilion. Terminal branches of n. facialis, a. labialis superioris and inferioris are placed at the deep plane of m. orbicularis oris.

The major muscle of the lip is m. orbicularis oris which gives volume to the lip and plays its sphincter function by surrounding the lip circularly. The upper lip is supplied by a. labialis superioris and lower lip is supplied by a. labialis inferioris. The sensorial innervation of the lower lip is provided by n. mentalis which is a terminal branch of the mandibular branch of n. trigeminus. The sensorial innervation of the upper lip is provided by n. infraorbitalis which is a terminal branch of the maxillary branch of n. trigeminalis. The motor innervation is supplied by the buccal and mandibular branches of n. Facialis.

The lymphatics of the lower lip are originated from the border of vermilion and constitute the collector branches. The lymph of the upper lip and commissure drain to the ipsilateral preauricular, infraparotid and level I lymph nodes. Since the embryological jointment of central frontonasal process separates the lateral maxillary processes and accompanying neurovascular and lymphatics, contralateral drainage does not occur. The lower lip is drained by cutaneous mucosal lymphatic capillaries. Lymphatic channels coming from this region terminated at the submental and submaxillary lymph nodes (level I and II lymph nodes).

There are many anastomoses crossing the midline and leading contralateral spread because of the connection between mandib-

ular processes at the midline. The lymphatics of lower lip are also included at the mental foramen in 22% of the cases. The second station in the lymphatic spread is level II lymph nodes and its spread can occur at level III lymph nodes as well.

The objectives of lip reconstruction

The major goals of lip reconstruction are: (i) avoidance of microstomia (ii) restoration of oral competence (iii) preservation of cutaneous sensation, (iv) maximizing cosmesis. The first condition for success in reconstructive surgery is to remove the tumor totally. Every reconstruction should be tailored individually. The surgical technique should be selected according to the defect size, location, thickness and also patient's condition and expectations.

The surgical procedures in lip reconstruction The classification schemes that are designed for lip defects are mainly based on anatomical location (cutaneous, vermilion, full-thickness), thickness (partial, full-thickness) and relative width of the defect compared to the size of the lip. In this review, the algorithm of the reconstruction techniques according to the location and size (between <1/2, 1/2-2/3 total, or near total) of the lip defects are presented (Figure 3) (44).

Cutaneous Defects

These defects are located on the surface of m. orbicularis oris and outer wall of the lips. It is necessary to be careful, because the flaps that are used to reconstruct the cutaneous defects may cause distortion at nasal root, oral cavity and melolabial crease (45). The small defects that involved the cutaneous and subcutaneous tissue can be reconstructed by primary closure parallel to the crease lines. The defects near the vermilion border can be reconstructed by A-T or O-T horizontal advancement flaps.

The medium or large cutaneous defects of the upper lip are generally reconstructed by transposition or rotation melolabial flap; on the other hand, the medium to large sized defects of the lower lip can be reconstructed by transposition and rotation flaps designed from the chin and cheek (Figure 4). The defects that are located at the midline can be reconstructed by unilateral or bilateral lip advancement flaps. Nguyen et al. (46) defined a double opposing V-Y advancement flap; in which both cutaneous/subcutaneous and mucosal tissues are advanced for the reconstruction of small full-thickness cutaneous/vermilion defects.

Vermilion-Mucosa Defects

These defects are generally formed in cases to whom vermilionectomy was performed for the treatment of actinic cheilitis, dysplasia or carcinoma in situ. Vermilionectomy is described as the excision of the diseased mucosa to the level of m. orbicularis oris. The surgical techniques preferred for the reconstruction of vermilion defects are: (i) primary closure, (ii) mucosal advancement flaps, (iii) interpolated mucosal cross-lip flaps, (iv) tongue flaps, and (v) vermilion muscle advancement flaps (45). Primary closure of vermilion defects is the easiest technique; however, it can only be performed to selected cases with small mucosal defects.

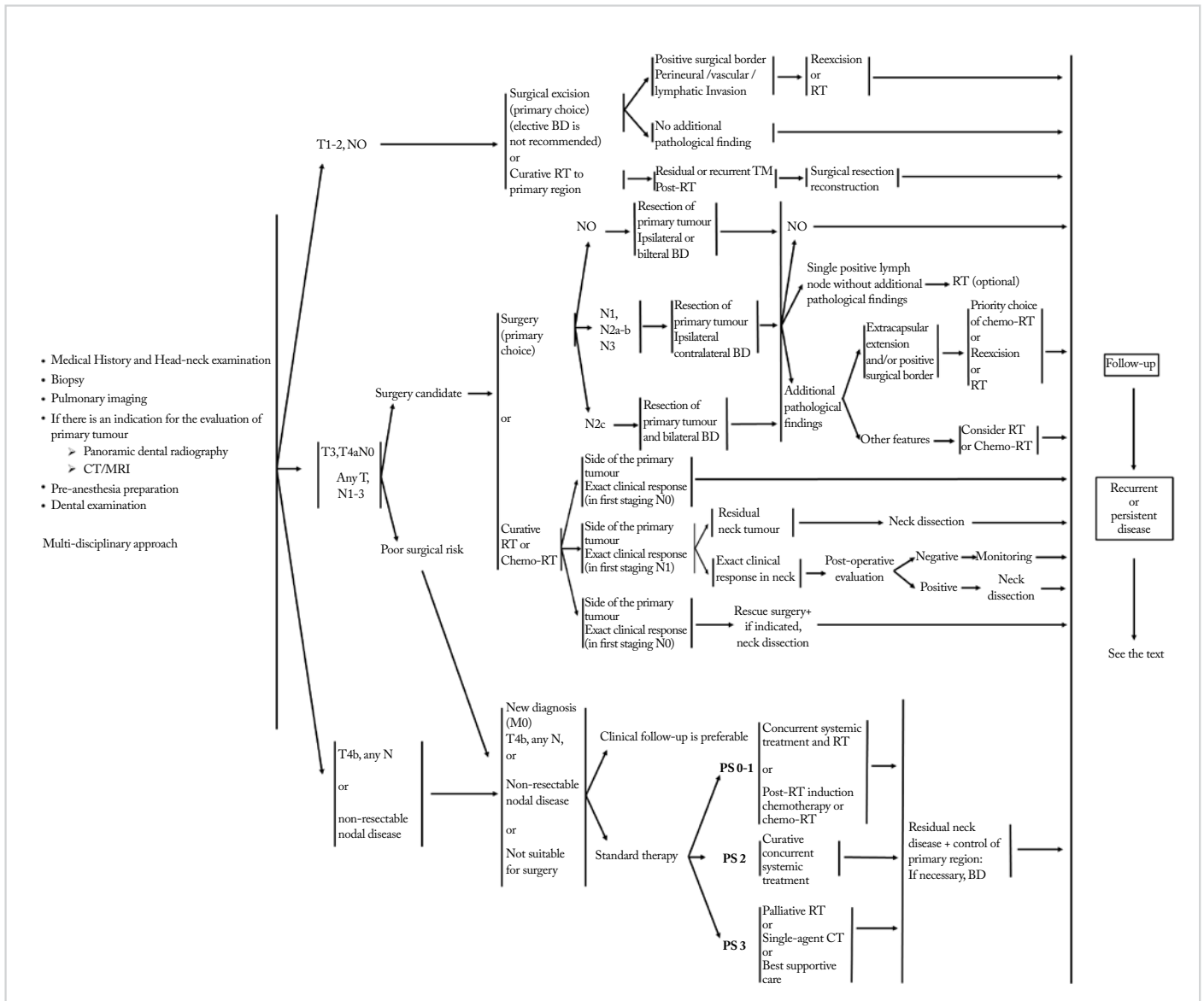


Figure 2. Treatment algorithm for lip cancers according to the 2013 *National Comprehensive Cancer Network* manual

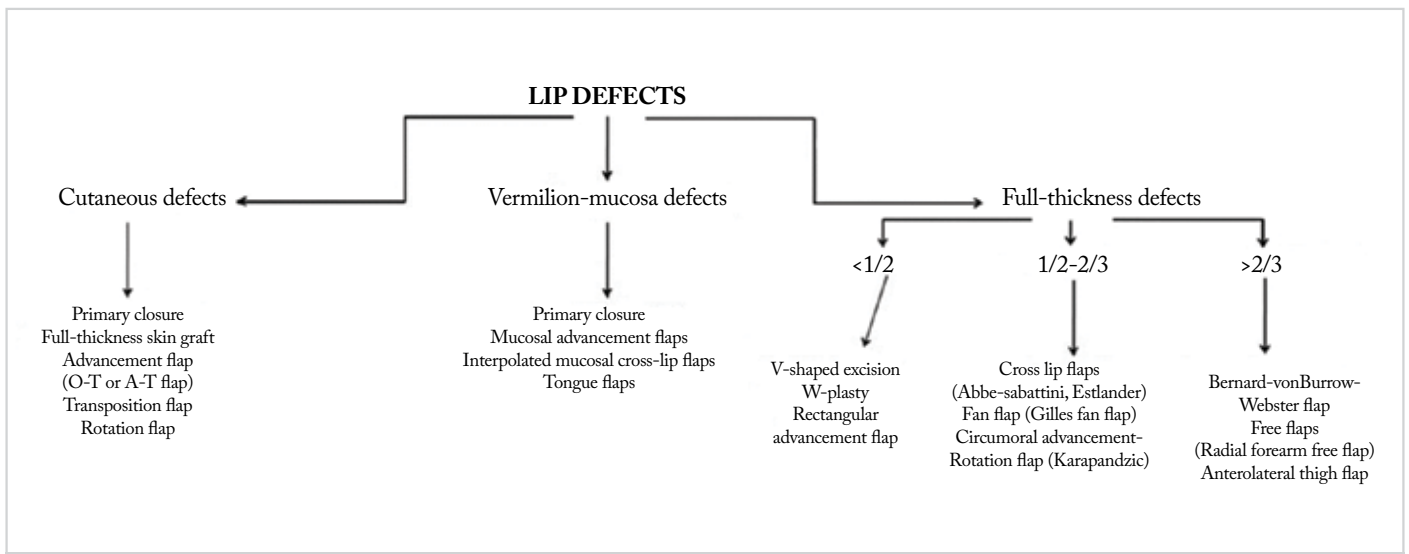


Figure 3. Algorithm of surgical reconstruction techniques for lip defects

The most common technique for the reconstruction of vermilion is mucosal advancement technique (Figure 5). The neighboring healthy mucosa can be dissected down to the gingivobuccal sulcus in a way that it remains at the depth of minor salivary gland and at the surface of the m. orbicularis oris, and a mucosal advancement flap is formed. The flap is advanced to the border of vermilion over m. orbicularis oris and sutured. A perfect aesthetic outcome can be achieved by this technique. However, wound contraction may cause distortion of the vermilion. Sand et al. compared the functional and aesthetic outcomes of primary closure and mucosal advancement flaps for the reconstruction of vermilion defects, and reported that the duration of the operation of mucosal advancement flaps is longer; however, it provides better functional and aesthetic outcomes (47).

Interpolated mucosal cross-lip flaps are recommended for wider vermilion defects. The flap which is formed by the elevation of sufficient mucosa and soft tissue, is transferred to the defect area and sutured. The most important disadvantage of this technique is the requirement of a time period of 2-3 weeks before the detachment of flap and requirement of a second surgical operation and the restriction of eating in order not to jeopardize the flap pedicle.

Tongue flaps are designed by the excision of sufficient mucosa and soft tissue from the ventral and lateral part of the tongue. Although they provide a good color match and tissue compatibility, they have similar disadvantages similar to interpolated mucosal cross-lip flaps. Therefore, they are appropriate to be used when bulkiness is required in wide mucosal or combined mucosa and muscle defects (Figure 6).

Vermilion muscle advancement flaps are formed by the lateral advancement of the tissue that is located near the defect area. These flaps are preferred in full-thickness vermilion defects which may include some part of the muscle underneath and not passing the one third of horizontal length of the lip. The flap is cut along the vermilion border and advanced towards the lateral border of the defect. It is necessary to be careful in order not to damage the a. labialis.

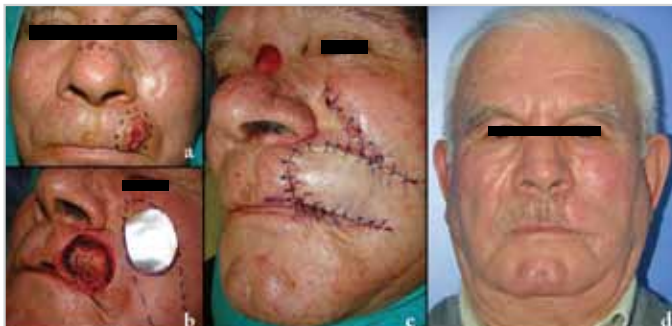

Figure 4. a-d. A case with an ulceronodular type BCC which is 2 cm in size and located at the upper lip laterally (a). Transposition flap designed from the nasolabial region after the tumor excision (b). Early view after transposition flap (c). Post operative 1. year view of the case (d)

BCC: basal cell carcinoma

Full-Thickness Defects

Since all layers are damaged in full-thickness defects of lip, an individualized reconstruction technique should be preferred. It is necessary to make an effort to provide continuity of m. orbicularis oris for its functionality. In addition, surgeon should be careful for the reconstruction of the vermilion border in order to achieve the best aesthetic outcome. The surgical techniques that are preferred for the reconstruction of full-thickness lip defects are grouped as follows (48, 49):

1. Reconstruction techniques in which remaining lip tissue is used: Wedge excision, W-plasty, lip advancement flaps.
2. Reconstruction techniques in which tissue transferred or rotated from the healthy lip: Abbe-Sabatini flap, Estlander flap, Gilles fan flap, Karapandzic flap.

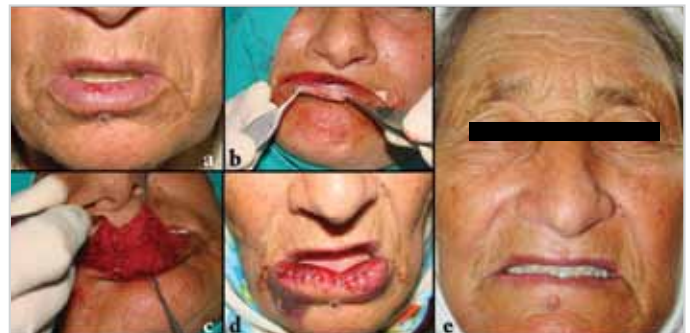

Figure 5. a-e. A case with actinic cheilitis on the lower lip (a). Mucosa excised after vermilionectomy (b). Dissection and elevation of lower lip mucosa up to the gingivobuccal line (c). Early view after mucosal advancement flap (d). The view of the case postoperative 6. month (e)

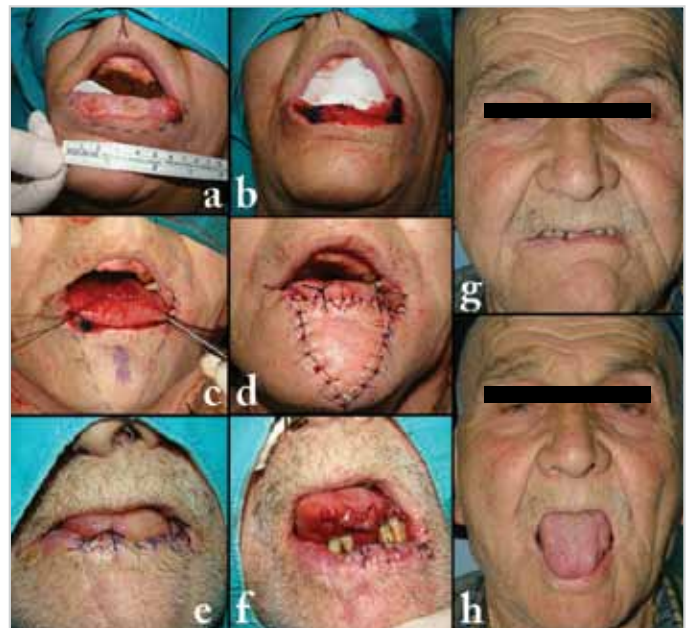

Figure 6. a-h. A case with a SCC on the lower lip which is 5.5 cm in size (a). View after tumor excision (b) V-Y advancement flap prepared on the outer wall of the lower lip and tongue flap designed for the reconstruction of mucosa (c). Early image after the reconstruction (d) Postoperative 3. week image of the case (e) Early view after separation of the tongue flap (f) Postoperative 2. year view of the case (g-h)

SCC: squamous cell carcinoma

3. Reconstruction technique in which adjacent cheek tissue is used: Bernard-von Burow-Webster flap.
4. Reconstruction techniques with free flaps: radial forearm free flap, free anterolateral thigh flap.

Surgical techniques used in the reconstruction of full-thickness lip defects are generally decided according to the defect size (Figure 3).

Full-Thickness Defects Involving Half of the Lip

Defects up to 30% of the transvers width of the lip can mostly be reconstructed without causing microstomia (49, 50). Soliman et al. (51) emphasized that better functional and aesthetic results are achieved by primary closure of full-thickness lip defects and suggested that local flaps are used more than necessary in lip reconstruction. They recommended the primary closure of defects that involved 40% of upper lip and 50% of lower lip, and emphasized that these rules are valid for geriatric patients who have a high level of loose tissue. When the lip tissue is excised, incisions must be designed according to the skin tension lines, and the terminal angle in the vertex must be approximately 30°. The most common techniques in the primary closure are wedge excision, primary closure and W-plasty (Figure 7,8).

Defects that involved more than one-third of the lip and smaller than half of the lip can be reconstructed with lip advancement flaps designed in rectangular shape (Figure 9).

Full Thickness Defects Involving one half to two-thirds of the Lip

Full thickness defects larger than one half of lip cannot be reconstructed by advancement of the remaining lip tissue; therefore, tissue transfer is necessary. The recommended surgical techniques for these defects are: Cross lip flaps (Abbe-Sabatini, Estlander); fan flap (Gillies fan Flap); and circumoral advancement-rotation flap (Karapandzic flap).

Cross lip flaps are designed by forming a full-thickness flap from the other lip. The width of the flap should be half of the width of the defect, thereby the widths of both lips can be equalized. In addition, the width of the flap should not be larger than 2 cm in size. The arterial supply of the flap is provided by labial artery; therefore, full thickness incisions should be designed according to the location of a labialis which is almost always localized just below the vermilion border. Then, the flap is flipped to the defect area and the donor area is closed primarily. The most important advantages of these flaps are the reconstruction of the defect by rather similar tissue and the provision of the continuity of muscle fibers.

Cross lip flaps are technically divided into two as Abbe-Sabatini and Estlander flaps. The Abbe-Sabatini flap is a two-staged procedure, especially preferred for defects that do not involve commissure (Figure 10). The pedicle is generally separated 2-3 weeks later. The most important disadvantage of Abbe-Sabatini flap is the deterioration at the vermilion line and inadequacy in lip adhesion.

Estlander flap is preferred for defects that involve the commissure. Although it is a one-staged procedure, it generally necessitates commissuroplasty due to the distortion at the commissure (Figure 11, 12). Rifaat defined a dual rhombic flap connected with a small lip displacement flap for the reconstruction of these defects. A superior rhombic flap is designed in a way that the distal part is located at the melolabial fold and an inferior rhombic flap is designed in such a way that the distal part is located at the labiomental sulcus. Both flaps are turned towards the commissure defect. The reconstruction also includes a small Estlander flap from the lower or upper lip (52).

The Gillies fan flap is a modification of the Estlander flap. A one sided Gillies fan flap is suitable for medium and large defects. A bilateral Gillies fan flap can also be used for near total lip defects;

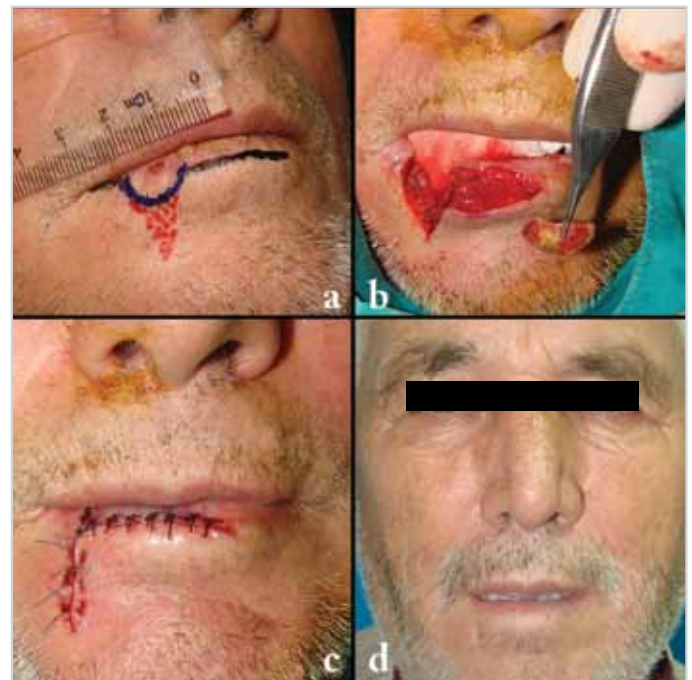

Figure 7. a-d. A case having an almost 1 cm SCC and actinic cheilitis on the lower lip (a). View after wedge resection and vermilionectomy (b,c). Postoperative 1. year view (d)

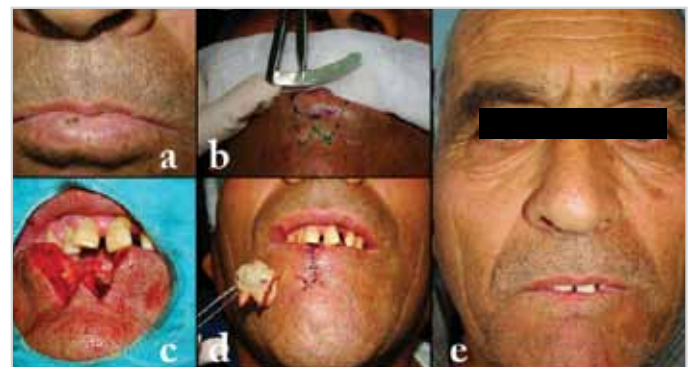

Figure 8. a-e. A case with a SCC of 1 cm in size that is located at the midline of lower lip (a). The design of tumor excision and W-plasty (b). Early view after tumor excision (c,d). Postoperative 3. year view

SCC: squamous cell carcinoma

however, microstomia, deterioration at vermilion line and rounded commissures are inevitable. Moreover, reversible denervation generally occurs and may lead to oral incompetence, even though the continuity of the m. orbicularis oris can be provided (53).

The Karapandzic flap is an advancement-rotation flap in which the lip is reconstructed by innervated m. orbicularis oris (Figure 13). In this flap, circumoral incisions are made from the nasolabial sulcus or from its parallel. Thereby, the remaining opposing lip tissue after excision is mobilized and reposed to reform the lip. The important thing is to protect the blood flow provided from the neurovascular bundle, a. labialis superior and inferior. The most important disadvantage of this flap is the potential risk of microstomia and blunting of the oral commissure.

Near Total or Total Lip Defects

The insufficiency of the remained lip tissue and the involvement of the nose, cheek, jaw, and/or other adjacent structures cause a difficulty for the reconstruction of near-total or total. Therefore, tissue transfer from peripheral tissues or from distant tissues that can be obtained by free flaps is of utmost important.

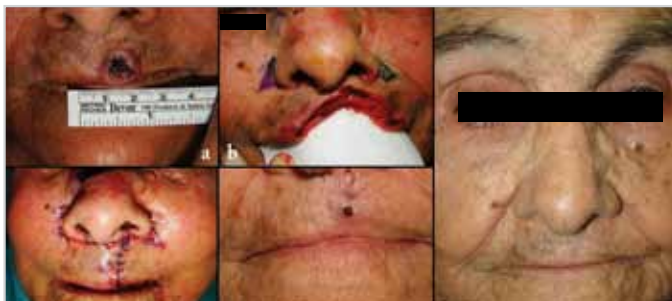

Figure 9. a-e. Ulceronodular type BCC case localized in the midline of the left lateral of the upper lip having a 1.5 cm. size (a). View after tumor excision and Burrow triangle design in bilateral alar region lateral (b) Early view after upper lip bilateral advancement flap (c) Postoperative 2. week and 3. year view (d,e)

BCC: basal cell carcinoma

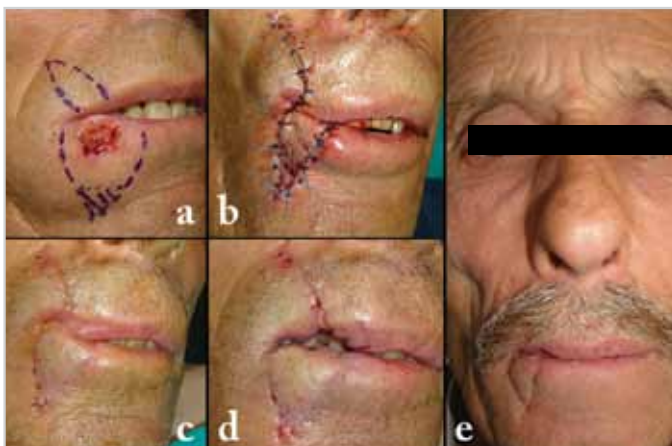

Figure 10. a-e. 2 cm sized lower lip right lateral localized SCC case and Abbe-Sabatini design (a). Postoperative early view (b). Postoperative 3. week view before Abbe-Sabatini flap separation (c). Early view after flap separation (d). Postoperative 2. year view (e)

SCC: squamous cell carcinoma

The Bernard-von Burrow-Webster flap is a regional flap preferred for this group of defects. It is based on the advancement of the remained lip tissue and bilateral cheek tissue. In this flap, cheek tissue and remained lip tissue are approximated and connected at the midline. Multiple Burrow triangles are excised to mobilize the cheek tissue. The elasticity of the cheek is the key point for the flap design, so it must certainly be evaluated preoperatively. The use of cheek tissue in this technique decreases the incidence of microstomia. In addition, the transfer of a static tissue may cause oral incompetence and salivation (48).

The Webster flap is formed by the excision of triangles in the lateral of both melolabial folds and labiomental sulcus and advancement of medial tissue. Mingowa et al. modified the Webster flap for the reconstruction of larger defects of the lower lip (54). They used the preserved melolabial tissue as a bridge for the defect emerging when the remaining lower lip tissue is cut near the normal commissure and advanced towards the contralateral commissure. Then, the reconstruction is completed by bringing a mucosal advancement flap over the melolabial flap.

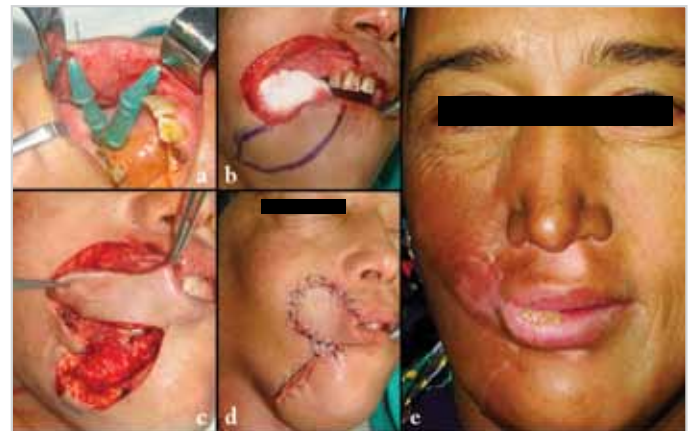

Figure 11. a-e. Almost 3 cm sized SCC case extending to the upper lip and buccal mucosa (a). Estlander flap design after tumor excision (b). View after turning the flap to the defect area (c). Early view after the surgery (d). Postoperative 6. month view (e)

SCC: squamous cell carcinoma

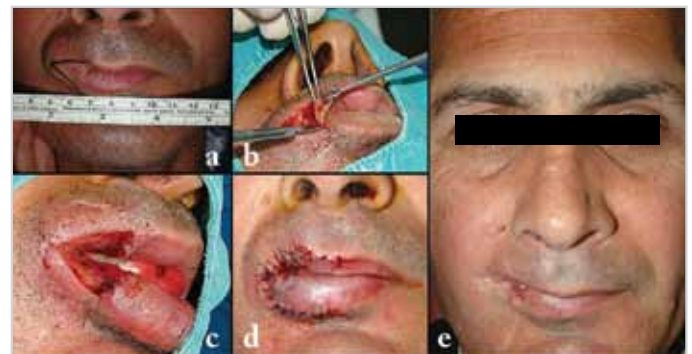

Figure 12. a-e. Commissuroplasty design after Estlander flap (a). Excision of cutaneous and subcutaneous tissue over M. orbicularis (b). View after the identification of the mucosa at the base of flap and turning it to the lower and upper lip (c,d). Postoperative 2th year view of the case (e)

Free flaps are the best alternatives for the repair of near-total or total lip defects. The most frequently preferred free flap is the radial forearm free flap. This flap can be obtained easily and has a long pedicle and capillaries, providing color and tissue compatibility. The arterial supply of radial forearm free flap is provided primarily from a. radialis. Although it is a fasciocutaneous flap, it may also include the palmaris longus tendon. The palmaris longus tendon can be connected with the remaining m. orbicularis oris and thereby, dynamic closure can be provided partially.

Carroll et al. (55) (10 patients), Özdemir et al. (56) (17 patients), and Jeng et al. (57) (12 patients) reported that the use of a radial forearm-palmaris longus tendon free flap for the reconstruction of near total and total lip defect was successful and could provide a good functional and aesthetic outcome. Moreover, the

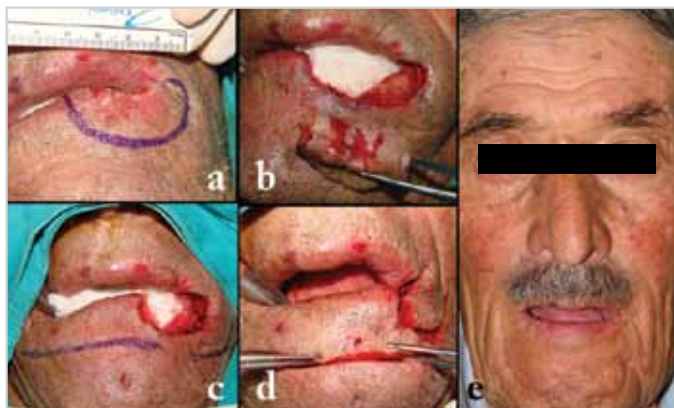

Figure 13. a-e. Almost 3 cm sized lower lip left lateral localized SCC case (a). View after tumor excision (b). View after Karapandzic flap design and flap shift (c,d). Postoperative 1. year view (e)
SCC: squamous cell carcinoma

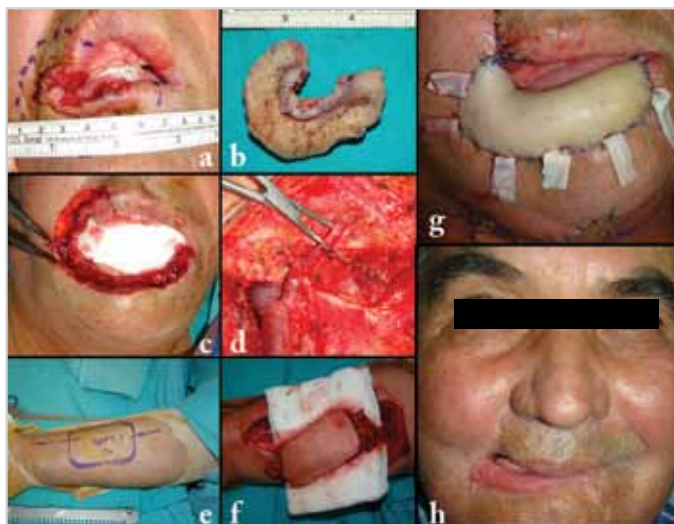

Figure 14. a-h. A case with a recurrent SCC involving three-quarters of the lower lip and one-third of the upper lip (a). The view of the excised tumor tissue (b). The view of the defect formed in the lip after excision (c). Demonstration of a. facialis in the neck and harvestment for microanastomose (d). The design of the almost 8.5x5.5cm-sized-flap (e). View after the flap elevation (f). View after the flap is located at the defect area (g). View 2 years and reconstruction of the lower lip by tongue flap (h)
SCC: squamous cell carcinoma

aesthetic outcome can be improved by additional surgeries, such as mucosal grafts, tongue flaps, vermilion tattoos, fat injections and liposuction (Figure 14). The most important disadvantage of this flap is the likelihood of development of oral incompetence, since it does not have dynamic features.

Conclusion

Lip cancers are the most common head and neck cancers, and they constitute an important health problem because of the functional and aesthetic role of the region. The chance of detecting these cancers at an early stage is considerably high, and thereby, they can be treated successfully. However, wide resections and complex reconstruction techniques are required for advanced stage lip cancers. The success in the surgical treatment of lip cancers depends on total removal of the tumor, protection or restoration of anatomical structures and functions of the lip as much as possible, and achievement of acceptable results aesthetically.

Informed Consent: Written informed consent was obtained from the patients.

Peer-review: Internally reviewed.

Author Contributions: Concept - G.T., G.E.; Design - G.T., G.E.; Supervision - G.E.; Funding - G.T., G.E.; Materials - G.T., G.E.; Data Collection and/or Processing - G.T., G.E.; Analysis and/or Interpretation - G.T., G.E.; Literature Review - G.T., G.E.; Writing - G.T., G.E.; Critical Review - G.E.; Other G.T., G.E.

Conflict of Interest: No conflict of interest was declared by the authors.

Financial Disclosure: The authors declared that this study has received no financial support.

References

1. Stucker FJ, Lian TS. Management Of Cancer Of The Lip, Operative Tech Otolaryngol 2004; 15: 226-33. [\[CrossRef\]](#)
2. Politi M, Salgarelli A, Panziera G, Cortelazzi R. Surgical treatment of neoplasms of the lip. Minerva Chir 1993; 48: 55-64.
3. Cooper JS, Porter K, Mallin K, Hoffman HT, Weber RS, Ang KK. National cancer database report on cancer of the head and neck: 10-year update. Head Neck 2009; 31: 748-58. [\[CrossRef\]](#)
4. McCombe D, MacGill K, Ainslie J, Beresford J, Matthews J. Squamous cell carcinoma of the lip: a retrospective review of the Peter MacCallum Cancer Institute experience 1979-88. Aust N Z J Surg. 2000; 70: 358-61. [\[CrossRef\]](#)
5. Zitsch RP. Carcinoma of the lip. Otolaryngol Clin North Am 1993; 26: 265-77.
6. Renner GJ, Zitsch RP. Cancer of the lip. In: Myers EN, Suen JY, eds. Cancer of the Head Neck. 3rd ed. Philadelphia: WB Saunders, 1996. p.294-320.
7. Wein RO, Weber RS. Oral kavitenin malign tümörleri. Cummings Otolaringoloji-BaşveBoyunCerrahisi. Güneş Tıp Kitapevleri 2007; 2: 1591.
8. Grover R, Douglas RG, Shaw JH. Carcinoma of the lip in Auckland, New Zealand, 1969-1987. Head Neck 1989; 11: 264-8. [\[CrossRef\]](#)
9. Heller KS, Shah JP. Carcinoma of the lip. Am J Surg 1979; 138: 600-3. [\[CrossRef\]](#)

10. Molnár L, Rónay P, Tapolcsányi L. Carcinoma of the lip. Analysis of the material of 25 years. *Oncology* 1974; 29: 101-21.
11. Visscher D Waal VD. Etiology of cancer of the lip. *Int J Oral Maxillofac Surg* 1998; 27: 199-203. [\[CrossRef\]](#)
12. Day TA, Davis BK. Oral cancer treatment. *Curr Treat Options Oncol* 2003; 4: 27-41. [\[CrossRef\]](#)
13. Akay BN, Erdem C. Squamous Cell Carcinoma. *TürkiyeKlinikleri J İntSci* 2007; 3: 20-37.
14. Petter G, Hausteiner UF. Histologic subtyping and malignancy assessment of cutaneous squamous cell carcinoma. *Dermatol Surg* 2000; 26: 521-30. [\[CrossRef\]](#)
15. McGuire JF, Ge NN, Dyson S. Nonmelanoma skin cancer of the head and neck I: histopathology and clinical behavior. *Am J Otolaryngol* 2009; 30: 121-33. [\[CrossRef\]](#)
16. Ashton KJ, Carless MA, Griffiths LR. Cytogenetic alterations in nonmelanoma skin cancer: A Review. *Genes, Chromosomes Cancer* 2005; 43: 239-48. [\[CrossRef\]](#)
17. Cassarino DS, Derienzo DP, Barr RJ. Cutaneous squamous cell carcinoma: a comprehensive clinicopathologic classification. Part one. *J Cutan Pathol* 2006; 33: 191-206. [\[CrossRef\]](#)
18. Ho T, Byrne PJ. Evaluation and initial management of the patient with facial skin cancer. *Facial Plast Surg Clin North Am* 2009; 17: 301-7. [\[CrossRef\]](#)
19. Bayramçılı M, Numanoglu A, Tezel E. The mental V-Y island advancement flap in functional lower lip reconstruction *Plast Reconstr Surg* 1997; 100: 1682-90. [\[CrossRef\]](#)
20. Dessinioti C, Antoniou C, Katsambas A, Stratigos AJ. Basal cell carcinoma: what's new under the sun. *Photochem Photobiol* 2010; 86: 481-91. [\[CrossRef\]](#)
21. Adışen E, Güler MA. Basal Cell Carcinoma. *TürkiyeKlinikleri J İntSci* 2007; 3: 10-9.
22. Kaya S. Lip Neoplasms. Çelik O, ed; *Otolaryngology-head and neck surgery. Atlas Tıp Kitapevi* 2007; 2: 623-38.
23. Broders AC. Squamous-cell epithelioma of the lip. *J Am Med Assoc* 1920; 74: 656-64. [\[CrossRef\]](#)
24. Edge SB, Byrd DR, Compton CC ve ark. *AJCC cancer staging manual* (7th ed). New York, NY: Springer; 2010.
25. Robbins KT, Malone J. Carcinoma of the oral cavity, pharynx & esophagus. 10th ed. In: Lee KJ, editör. *Essential Otolaryngology-Head & Neck Surgery*. McGraw Hill companies, 2012. pp.700-2.
26. Bath-Hextall FJ, Perkins W, Bong J, Williams HC. Interventions for basal cell carcinoma of the skin. *Cochrane Database Syst Rev* 2007; 1: CD003412.
27. Cruise CW, Radocha RF. Squamous cell carcinoma of the lip. *Plast Reconstr Surg* 1987; 80: 787-91. [\[CrossRef\]](#)
28. Neville JA, Welch E, Leffell DJ. Management of nonmelanoma skin cancer in 2007. *Nat Clin Pract Oncol* 2007; 4: 462-9. [\[CrossRef\]](#)
29. Luce EA. Carcinoma of the lower lip. *Surg Clin North Am* 1986; 66: 3-11.
30. Visscher JGAM, Gooris PJJ, Roodenburg JLN. Surgical margins for resection of squamous cell carcinoma of the lower lip. *Int J Oral Maxillofac Surg* 2002; 31: 154-57. [\[CrossRef\]](#)
31. Lee DA, Miller SJ. Nonmelanoma skin cancer. *Facial Plast Surg Clin North Am* 2009; 17: 309-24. [\[CrossRef\]](#)
32. Ridky TW. Nonmelanoma skin cancer. *J Am Acad Dermatol* 2007; 57: 484-501. [\[CrossRef\]](#)
33. de Visscher JG, Botke G, Schakenraad JA, van der Waal I. A comparison of results after radiotherapy and surgery for stage I squamous cell carcinoma of the lower lip. *Head Neck* 1999; 21: 526-30. [\[CrossRef\]](#)
34. Langdon JD, Ord RA. The surgical management of lip cancer *J Craniofac Surg* 1987; 15: 281-7. [\[CrossRef\]](#)
35. Casino AR, Toledano IP, Jorge JF. Brachytherapy in lip cancer. *Med Oral Patol Oral Cir Bucal* 2006; 11: 223-9.
36. Kishi K, Matsunaka M, Sato M, Sonomura T, Sakurane M, Uede K. T1 and T2 lip cancer: A superselective method of facial arterial infusion therapy-A preliminary study. *Radiology* 1999; 213: 173-9. [\[CrossRef\]](#)
37. Wu CF, Chen CM, Chen CH, Shieh TY, Sheen MC. Continuous intraarterial infusion chemotherapy for early lip cancer. *Oral Oncol* 2007; 43: 825-30. [\[CrossRef\]](#)
38. Baker SR, Krause CJ. Carcinoma of the lip. *Laryngoscope* 1980; 90: 19-27. [\[CrossRef\]](#)
39. Veness MJ, Ong C, Cakir B, Morgan G. Squamous cell carcinoma of the lip. Patterns of relapse and outcome: Reporting the Westmead Hospital Experience, 1980-1997. *Australasian Radiology* 2001; 45: 195-9. [\[CrossRef\]](#)
40. Million RR, Cassisi NJ. [Oral cavity]. *Management of the Head and Neck Cancer*. Philadelphia: JB Lippincott Company; 1984. p.239-98.
41. Dinehart SM, Pollack SV. Metastases from squamous cell carcinoma of the skin and lip. An analysis of twenty-seven cases. *J Am Acad Dermatol* 1989; 21: 241-8. [\[CrossRef\]](#)
42. Altinyollar H, Berberoğlu U, Celen O. Lymphatic mapping and sentinel lymph node biopsy in squamous cell carcinoma of the lower lip. *Eur J Surg Oncol* 2002; 28: 72-4. [\[CrossRef\]](#)
43. Khalil HH, Elaff AH, Afifi A, Alsayed Y, Mahboub T, El-Refai KM. Sentinel lymph node biopsy in management of N0 stage T1-T2 lip cancer as a "same day" procedure. *Oral Oncol* 2008; 44: 608-12. [\[CrossRef\]](#)
44. Eskiizmir G, Baker S, Cingi C. Nonmelanoma skin cancer of the head and neck: reconstruction. *Facial Plast Surg Clin North Am* 2012; 20: 493-513. [\[CrossRef\]](#)
45. Renner GJ. Reconstruction of the lip. 3rd ed. In: Baker S, editor. *Local flaps facial reconstruction*. Philadelphia; 2007. pp.475-524.
46. Nguyen DT, Oki K, Hyakusoku H, Ogawa R. Upper lip basal cell carcinoma reconstruction based on anatomical characteristics using skin-mucosa double opposing v-y advancement fl. *Eplasty* 2011; 11: 26.
47. Sand M, Altmeyer P, Bechara FG. Mucosal advancement flap versus primary closure after vermilionectomy of the lower lip. *Dermatol Surg* 2010; 36: 1987-92. [\[CrossRef\]](#)
48. Coppit GL, Lin DT, Burkey BB. Current concepts in lip reconstruction. *Curr Opin Otolaryngol Head Neck Surg* 2004; 12: 281-7. [\[CrossRef\]](#)
49. Cupp C, Larrabee WF. Reconstruction of the lips. *Op Tech Otolaryngol Head Neck Surg* 1993; 4: 46-53. [\[CrossRef\]](#)
50. Baumann D, Robb G. Lip reconstruction. *Semin Plast Surg* 2008; 22: 269-80. [\[CrossRef\]](#)
51. Soliman S, Hatef DA, Hollier LH Jr, Thornton JF. The rationale for direct linear closure of facial Mohs' defects. *Plast Reconstr Surg* 2011; 127: 142-9. [\[CrossRef\]](#)
52. Rifaat MA. Reconstruction of medium-sized defects of oral commisure by combining double full-thickness cheek rhomboidal flaps and a small lip switch flap. *Ann Plast Surg* 2011; 67: 134-8. [\[CrossRef\]](#)
53. McCarn KE, Park SS. Lip reconstruction. *Otolaryngol Clin North Am* 2007; 40: 361-80. [\[CrossRef\]](#)
54. Minagawa T, Maeda T, Shioya R. Esthetic and safe lower lip reconstruction of an asymmetric defect due to cancer resection: a modified Webster method combined with a nasolabial flap. *J Oral Maxillofac Surg* 2011; 69: 256-9. [\[CrossRef\]](#)
55. Carroll CM, Pathak I, Irish J, Neligan PC, Gullane PJ. Reconstruction of total lower lip and chin defects using the composite radial forearm-palmaris longus tendon free flap. *Arch Facial Plast Surg* 2000; 2: 53-6. [\[CrossRef\]](#)
56. Ozdemir R, Ortak T, Koçer U, Celebioğlu S, Sensöz O, Tiftikcioglu YO. Total lower lip reconstruction using sensate composite radial forearm fl. *J Craniofac Surg* 2003; 14: 393-405. [\[CrossRef\]](#)
57. Jeng SF, Kuo YR, Wei FC, Su CY, Chien CY. Total lower lip reconstruction with a composite radial forearm-palmaris longus tendon flap: a clinical series. *Plast Reconstr Surg* 2004; 113: 19-23. [\[CrossRef\]](#)