

Laryngeal Verruca Vulgaris Presenting with Dysphonia: A Case Report

Case Report

Sibel Yıldırım, Zahide Çiler Tezcaner, Tural Fatullayev, Gürsel Dursun
 Department of Otorhinolaryngology, Ankara University School of Medicine, Ankara, Turkey

Abstract

Verruca vulgaris is a common skin lesion that is associated with human papilloma virus and is observed on the surface of skin. Verruca vulgaris is rarely seen in mucosal membranes. Atypical locations may be confused with verrucous carcinoma. The incidence of laryngeal verruca vulgaris has not yet been reported in the literature. Differential diagnoses in histopathological examinations include keratosis, squamous

papilloma, verrucous hyperplasia, and verrucous carcinoma. Distinguishing disease from verrucous carcinoma is particularly important because the treatment approach can be altered. In this report, we present a rare case of laryngeal verruca vulgaris that was diagnosed on the basis of histopathological features.

Keywords: Dysphonia, larynx, verruca vulgaris

Introduction

Verruca vulgaris is a frequently encountered skin lesion caused by human papilloma virus (HPV). The lesions can be seen on the hands, arms, and legs; however, they can also settle on the surface of the skin in any region of the body or more rarely in the mucosal membranes (1). Morphologically, they are papules or nodules that are flat or pedunculated, hyperkeratotic, and skin colored. Laryngeal localization of verruca vulgaris, which is also observed on mucosal surfaces such as the lip and oral cavity, is not frequent (2). Laryngeal verruca vulgaris can easily be confused with other laryngeal lesions, especially with verrucous carcinoma.

Limited cases of laryngeal verruca vulgaris have been reported in the literature. Extensive surgical resections may be performed in patients with laryngeal verruca vulgaris because it can be confused clinically with verrucous carcinoma (2). In this case report, laryngeal verruca vulgaris was discussed in the light of literature and it was aimed to emphasize a benign laryngeal lesion considered in verrucous lesions for preventing unnecessary large resections.

Case Report

A 55-year-old male patient presented with a complaint of hoarseness that had existed for one year and had increased over time. The patient had a history of smoking 60 packs of cigarettes per year and no history of alcohol use. No wart-like lesions were identified in other parts of his body or in the family history. In the laryngostroboscopic examination, an intracordal mass lesion was located in the middle one-third part of the right vocal cord, which had a nodular appearance, keratotic foci on the medial surface, and disrupted the vibratory pattern in the stroboscopy (Figure 1). It was determined that the mass caused reactive changes in the opposite vocal cord and an irregularity in the medial surface of the cord. The other laryngeal mucosal surfaces were observed to be normal. The patient underwent direct laryngoscopy under general anesthesia, and the lesion observed on the right cord was completely excised.

Histopathological examination of the lesion revealed papillary structures presenting with hyperkeratosis, hypergranulosis, elongated rete showing a tendency to converge towards the center on a large and flat ground, and koilocytes in the spinous



Cite this article as: Yıldırım S, Tezcaner ZÇ, Fatullayev T, Dursun G. Laryngeal verruca vulgaris presenting with dysphonia: a case report. Turk Arch Otorhinolaryngol 2017; 55: 184-6.

This study was presented at the 38th Turkish National Congress of Otorhinolaryngology Head and Neck Surgery, 26-30 October 2016, Antalya, Turkey.

Address for Correspondence:

Sibel Yıldırım
 E-mail: yldrmsib@gmail.com

Received Date: 28.08.2017

Accepted Date: 08.10.2017

© Copyright 2017 by Official Journal of the Turkish Society of Otorhinolaryngology and Head and Neck Surgery Available online at www.turkarchotorinolaryngol.net

DOI: 10.5152/tao.2017.2769

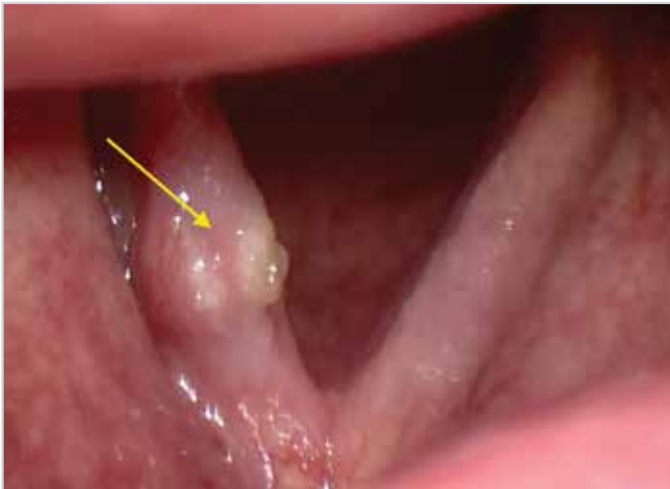

Figure 1. Mass lesions with nodular appearance located in the middle one-third of the right vocal cord

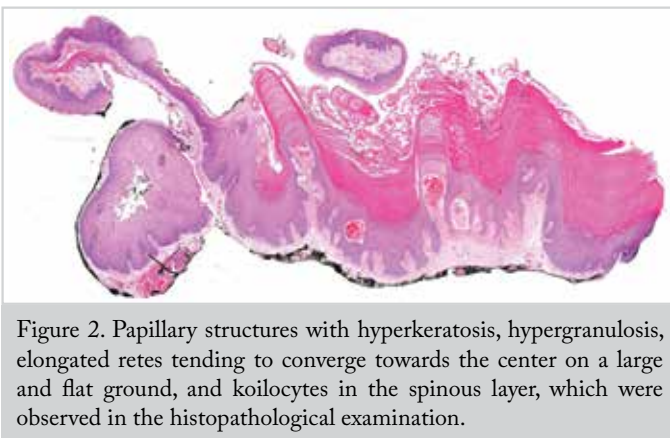


Figure 2. Papillary structures with hyperkeratosis, hypergranulosis, elongated rete tenders converging towards the center on a large and flat ground, and koilocytes in the spinous layer, which were observed in the histopathological examination.

layer and the lesion was determined to be consistent with verruca vulgaris (Figure 2). The molecular examination demonstrated negative high- and low- risk HPV.

No problems were found in the patient who was followed up with endoscopic examinations in terms of recurrence 1, 3, and 9 months post-operatively (Figure 3). Verrucous lesions were not found on other parts of the body of the patient; the patient's complaints of hoarseness also recovered. Informed consent was obtained from the patient for publication purposes.

Discussion

Verruca vulgaris of the skin is one of the most common clinical forms of HPV in humans and involves one or more small, round, puffy, and painless lesions. Apart from the skin, verruca vulgaris can also be seen on the mucosal surfaces, particularly on the lips and in the oral cavity. The clinical occurrence of laryngeal verruca vulgaris is rare (2). Thirteen patients diagnosed with laryngeal verruca vulgaris have been reported in the literature (2-6).

HPV, a member of papilloma viridae family, is the cause of verruca vulgaris involving the skin and mucous membranes. These envelope-free viruses with icosahedral nucleocapsid are 50-55 nm in diameter and contain a double-stranded and protein-encapsulated DNA genome. More than 200 HPV types

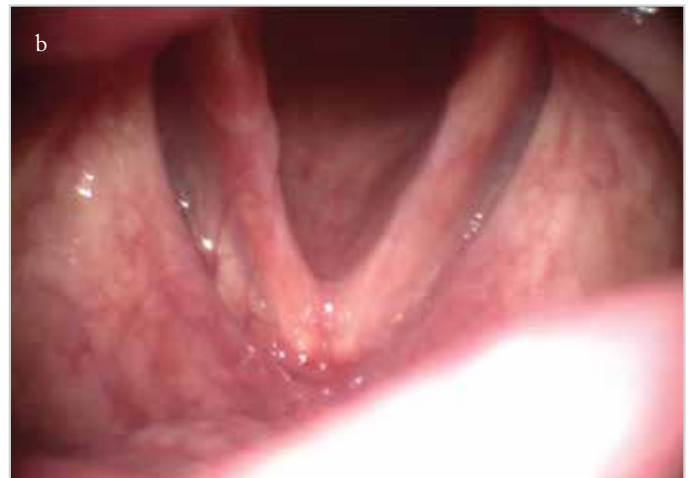
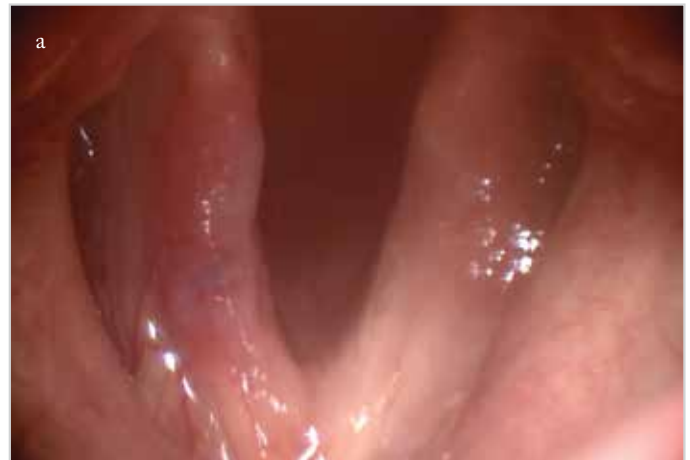
Figure 3. a, b. Endoscopic appearance in the postoperative third month (a), endoscopic appearance in the postoperative ninth month (b)

have been described (5). The cause of cutaneous verruca vulgaris is generally reported as type 2 HPV and type 4 HPV. However, HPV subtypes have been studied in a patient diagnosed with laryngeal verruca vulgaris in literature, and contrary to the type 2 and 4, which are frequently observed in cutaneous verruca vulgaris, HPV positivity has been found in type 6 and 11 (5). HPV positivity could not be demonstrated in the other two cases reported in the literature (3, 4). HPV was studied immunohistochemically in our patient, and low- or moderate-risk HPV positivity was not found. Verruca vulgaris was diagnosed considering the histopathological features of the lesion. Differential diagnoses in the histopathological examination should include keratosis, squamous papilloma, verrucous hyperplasia, and verrucous carcinoma (2). Koilocytosis observed in verruca vulgaris is important in the histopathological differentiation between verruca vulgaris and simple keratosis. Furthermore, in contrast to laryngeal verruca vulgaris, different degrees of atypia can be observed in keratosis.

Fechner et al. (2) presented two patients who had superficial keratotic vocal cord lesions and underwent hemilaryngectomy with the diagnosis of verrucous carcinoma, and in whom local excision was performed due to the diagnosis of squamous papilloma. Laryngeal verruca vulgaris was first described when the histopathological features of the lesions were observed to be

similar to those of cutaneous verruca vulgaris. Because the cases of laryngeal verruca vulgaris might have been missed out due to a misdiagnosis in the past, it is impossible to state an opinion about its exact incidence. In literature, only one female patient has been reported to have laryngeal verruca vulgaris yet (5). It can be assumed that the lesion is seen more frequently in men, and our case also involved a male.

Laryngeal verruca vulgaris is frequently confused with verrucous carcinoma due to its clinical appearance. Verruca vulgaris and verrucous carcinoma can be distinguished histopathologically. While papillary structures with hyperkeratosis and hypergranulosis are intensely observed in laryngeal verruca vulgaris, there are no significant granular cells and keratohyalin granules in verrucous carcinoma. Koilocytes in the spinous layer are an important histological finding for the laryngeal verruca vulgaris. Although koilocytotic cells can also be seen in verrucous carcinoma, it is much less common compared to laryngeal verruca vulgaris. Elongated retes with a tendency to converge at the center on a large and flat ground are observed in laryngeal verruca vulgaris. These retes are larger in verrucous carcinoma, and there are usually no lamina propriae among them and they are also seen in a packed form (7). In verrucous carcinoma, compared with laryngeal verruca vulgaris, more intense lymphocytic infiltration and inflammation are found in the stroma (8). Stromal invasion is the most important finding that suggests verrucous carcinoma. Laryngeal verruca vulgaris, verrucous hyperplasia, and verrucous carcinoma can be distinguished depending on the depth of invasion. To evaluate the depth of invasion and to avoid misdiagnosis, the orientation of the pathologist to the prepare gains importance for these types of lesions.

While verrucous carcinoma requires a more aggressive treatment, literature supports the idea that total excision of the lesion is sufficient for verruca vulgaris. None of the reported cases showed recurrence after total excision. While the longest follow-up period is 17 years for one case, the results of 6-12 month follow-up on average have been reported (2-6). There was no evidence suggesting recurrence during the 9-month follow-up of our case.

Although the same virus family is involved in the etiology of laryngeal papillomatosis and laryngeal verruca vulgaris, they can be distinguished clinically and histologically. Juvenile papillomatosis consists of large numbers of small and sometimes merging papillomas and is usually seen in children and sometimes in the adults. On a laryngoscopic examination, the papillomas appear pink in color and typically involve vocal cords and ventricular bands, and they may settle in all other laryngeal structures and in the tracheobronchial airway (9). Laryngeal verruca vulgaris is usually seen as a single, white-colored keratotic lesion. While no recurrence has been reported in verruca vulgaris, it is frequently seen in laryngeal papillomatosis. Histopathologically, the papillomas associated with juvenile papillomatosis have little or no surface keratinization, and they contain no keratohyalin granules (10). Verruca vulgaris is characterized by severe keratinization and diffuse keratohyalin granulomas. Koilocytosis is observed in both lesions, but it is more common in verruca vulgaris.

Conclusion

Laryngeal verruca vulgaris has rarely been reported in the literature. In verrucous lesions of the larynx, verruca vulgaris should be considered in terms of the differential diagnosis. In this case report, the clinical features of laryngeal verruca vulgaris were discussed by comparing with those reported in the literature, and we aimed to emphasize the features that should be considered in the differential diagnosis through histopathological findings. To comment on the clinical behavior of laryngeal verruca vulgaris, more cases and long-term follow-up results are needed.

Informed Consent: Written informed consent was obtained from patient who participated in this study.

Peer-review: Externally peer-reviewed.

Author Contributions: Concept - S.Y., Z.Ç.T., T.F.; Design - S.Y., Z.Ç.T., G.D.; Supervision - S.Y., Z.Ç.T., G.D.; Resource - S.Y., Z.Ç.T., T.F.; Materials - S.Y., Z.Ç.T., T.F.; Data Collection and/or Processing - S.Y., Z.Ç.T., T.F.; Analysis and/or Interpretation - S.Y., Z.Ç.T.; Literature Search - S.Y., Z.Ç.T.; Writing - S.Y.; Critical Reviews - G.D.

Conflict of Interest: No conflict of interest was declared by the authors.

Financial Disclosure: The authors declared that this study has received no financial support.

References

1. Lipke MM. An armamentarium of wart treatments. *Clin Med Res* 2006; 4: 273-93. [\[CrossRef\]](#)
2. Fechner RE, Mills SE. Verruca vulgaris of the larynx: a distinctive lesion of probable viral origin confused with verrucous carcinoma. *Am J Surg Pathol* 1982; 6: 357-62. [\[CrossRef\]](#)
3. Acar B, Babademez MA, Karabulut H, Karasen RM. An unusual cause of dysphonia: laryngeal verruca vulgaris. *B-ENT* 2009; 5: 183-7.
4. Topdag M, Erdogan S, Kara A, Derin S. Laryngeal verruca vulgaris. *BMJ Case Rep* 2015; pii: bcr2014207773. [\[CrossRef\]](#)
5. Barnes L, Yunis EJ, Krebs FJ 3rd, Sonmez-Alpan E. Verruca vulgaris of the larynx. Demonstration of human papillomavirus types 6/11 by in situ hybridization. *Arch Pathol Lab Med* 1991; 115: 895-9.
6. Sagit M, Hira I, Polat H, Akay E, Yasar M. A rare cause of hoarseness: laryngeal verruca vulgaris. *J Craniofac Surg* 2016; 27: e3978. [\[CrossRef\]](#)
7. Nostrand AWP, Olofsson J. Verrucous carcinoma of the larynx. A clinical and pathological study of 10 cases. *Cancer* 1972; 30: 691-702. [\[CrossRef\]](#)
8. Maurizi M, Cadoni G, Ottaviani F, Rabitti C, Almadori G. Verrucous squamous cell carcinoma of the larynx: Diagnostic and therapeutic considerations. *Eur Arch Otorhinolaryngol* 1996; 253: 130-5. [\[CrossRef\]](#)
9. Wiatrak BJ. Overview of recurrent respiratory papillomatosis. *Curr Opin Otolaryngol Head Neck Surg* 2003; 11: 433-41. [\[CrossRef\]](#)
10. Batsakis JG, Raymond AK, Rice DH. The pathology of head and neck tumors: papillomas of the upper aerodigestive tracts, Part 18. *Head Neck Surg* 1983; 5: 332-44. [\[CrossRef\]](#)