


Metastatic Renal Cell Carcinoma of the Nasal Septum: A Case Report

Case Report ▶

Mustafa Aslier , Mustafa Cenk Ecevit 

Department of Otorhinolaryngology, Dokuz Eylül University Faculty of Medicine, İzmir, Turkey

Abstract ▶

Metastatic lesions of the nasal cavity and paranasal sinuses are rare tumors. Carcinomas originating from intrapelvic organs play an important role in the differential diagnosis of these masses because of their paradoxical spread to the head and neck region. In this study

we report a case with metastatic renal cell carcinoma of the caudal nasal septum.

Keywords: Nasal septum, nose neoplasms, renal cell carcinoma

Introduction

Masses identified in the sinonasal region for the most part consist of non-neoplastic inflammatory lesions (1). These lesions can be differentiated from neoplastic pathologies in that they often show bilateral development in the nasal cavity. Risk of neoplasia is higher in unilateral intranasal masses and therefore should be investigated with advanced examination techniques even if they appear like an inflammatory polyp. Mucosal edema and polypoid degeneration that can develop around the lesion due to the inflammation caused by the tumoral lesion can challenge detection of the malignant mass and even affect the quality of the biopsy sample.

veins, and through this plexus, embolus-forming carcinoma cells entering the intravascular system can reach the head and neck region without going through the pulmonary circulation (4).

In this study we present the case of a patient with unilateral symptoms and was diagnosed following biopsy of the intranasal mass. In reference to this case we discuss the diagnosis and treatment approaches with review of the literature and similar case series.

Case Presentation

The 63-year-old male patient presented to the Department of Otorhinolaryngology of Dokuz Eylül University with complaints of recent nasal congestion and occasional nose bleeding in the left nasal cavity. In his physical examination, a caudally localized solid mass of about 2 cm on the left nasal septum was observed to obstruct the nasal vestibule (Figure 1). Incisional biopsy taken from the anterior of the lesion was reported as RCC metastasis. The patient was referred to the Department of Urology where radiological examination was performed to identify the primary site. The radiological imaging revealed a 6-cm mass in the right kidney, and metastasis screening revealed a mass lesion in the right proximal femur. Tru-cut biopsy of the kidney revealed RCC. Palliative chemother-

As mentioned above, neoplastic lesions of the sinonasal region usually develop unilaterally. While malignant lesions are rare tumors, metastatic masses are highly rare in this group. To name in the order of frequency, renal cell carcinoma (RCC), bronchogenic carcinoma, thyroid and breast carcinomas, prostate tumors can metastasize to the sinonasal region (2). Particularly RCC is the most common metastatic tumor of this region (3).

This paradoxical spread of the tumors originating from intrapelvic organs can occur through Batson's venous plexus.⁴ Batson's venous plexus is located between deep pelvic veins and internal vertebral



ORCID IDs of the authors:
M.A. 0000-0001-8257-0979;
M.C.E. 0000-0002-5809-7322.

Cite this article as: Aslier M, Ecevit MC.
Metastatic Renal Cell Carcinoma of the
Nasal Septum: A Case Report. *Turk Arch
Otorhinolaryngol* 2018; 56: 51-3.

This study was presented as a poster presentation at the 33rd Turkish National Congress of Otorhinolaryngology Head and Neck Surgery, October 26-30, 2011, Antalya, Turkey.

Corresponding Author:
Mustafa Aslier
E-mail: mustafa.aslier@gmail.com

Received Date: 15.10.2017
Accepted Date: 03.11.2017

© Copyright 2018 by Official Journal of the Turkish Society of Otorhinolaryngology and Head and Neck Surgery Available online at www.turkarchotolaryngol.net

DOI: 10.5152/tao.2018.2826

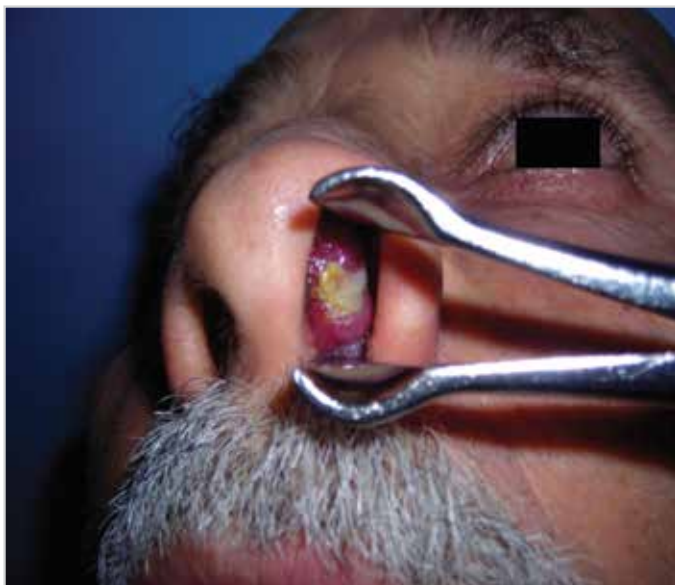

Figure 1. Renal cell carcinoma metastasis developed in the caudal portion of nasal septum

apy was planned, and the patient was referred to the Department of Medical Oncology. At this stage informed written consent was obtained from the patient for an scientific publication.

Given the advanced-stage of the patient's metastatic condition, curative intervention was not performed for treating the intranasal mass. Chemotherapy protocol was implemented by the Department of Medical Oncology. The patient did not respond to the treatment and passed away at the end of first month due to multiple organ failure caused by disseminated disease.

Discussion

A majority of intranasal masses consist of nasal polyps caused by chronic inflammation (1). Nasal polyps can be identified easily since they develop bilaterally, and biopsy is often not necessary before the treatment. Unilateral masses identified in the sinonasal region, however, should necessarily be investigated for non-inflammatory pathologies. Prioritizing imaging will be suitable to that end. With imaging techniques, masses such as encephalocele or meningocele that extend intracranially can be differentially diagnosed, and biopsy procedures that can lead to catastrophic outcomes can be avoided. Malignancy probability is high in the presence of a unilateral, solid mass which is identified to have invaded the surrounding structures or caused bone destruction. In such cases tissue sample should be obtained as soon as possible for histopathological diagnosis.

The most significant group of malignant lesions of the sinonasal region consists of primary tumors. Most common tumors of this group include epidermoid carcinoma, and less commonly tumors originating from minor salivary gland neoplasia, malignant melanoma and olfactory mucosa (1, 5). Metastatic tumors are quite rare and macroscopically difficult to discriminate from a primary tumor. The mass can be identified as metastatic after histopathological examination of the tissue sample. Malignancies metastasizing to the sinonasal region

include, in the order of frequency, RCC, bronchogenic carcinoma, thyroid and breast carcinomas, and prostate tumors (2). Of these metastatic masses, tumors originating from intrapelvic organs are significant due to their ability to paradoxically spread to the head and neck region.

Between the deep pelvic veins that drain the urinary system and the prostate, and the internal vertebral veins lies a collateral circulation system. This vascular collateral system was Described by Oscar Vivian Batson in 1940 and named after him as Batson's Venous Plexus (4). Through this plexus, tumors that originate from organs such as the urinary system, the prostate or the rectum can metastasize to the head and neck region without entering the pulmonary circulation (4, 6, 7). Likewise, RCC is a type of tumor that can metastasize to the head and the neck with this mechanism (8, 9). There are RCC cases reported in the literature with isolated metastasis to the highly vascularized regions of the head and neck, i.e., the nasal cavity and the paranasal sinuses (3, 9). Some of these cases were diagnosed based on biopsies taken from intranasal masses.

In this study, search was conducted in PubMed using the MeSH keywords 'Renal Cell Carcinoma' and 'Head and Neck Neoplasms' to assess the RCC cases with metastases to the head and neck region. A total of 73 articles published between 1956 to 2016 about 111 cases were accessed. Review of the cases reported in these studies showed that RCC could metastasize to almost any region of the head and neck, however, was more frequently seen in the sinonasal region (20 cases), in the cervical lymph nodes (17 cases), the skin (12 cases), the tongue (10 cases), the parotid gland (9 cases) and the thyroid glands (7 cases). The result of this review showed that metastases to the head and neck region in the reported RCC cases most commonly developed in the sinonasal region. In the presented case, metastatic focus was also in the sinonasal region.

With regard to the oncologic behavior of the RCC, it is known to be an aggressive tumor that disseminates hematogenously. Metastasis develops in 33% of the patients and the rate of 2-year survival is 10 to 20%.¹⁰ In early-stage cases that fall into the low-risk group, survival time has been shown to increase with metastasectomy. Therefore, metastatic screening should be the first procedure to be performed after diagnosis. Isolated metastases identified as a result of screening indicate curative treatment (10). Palliative treatment options should be used in cases presenting with disseminated disease.

As mentioned above, metastatic screening should be prioritized in cases identified to have RCC metastasis to the head and neck region. This will help to avoid extensive surgeries that have not been shown to contribute to patient survival in cases with disseminated disease. In cases with isolated metastasis to the head and neck region, however, primary surgical treatment together with curative treatment of the metastatic focus should be planned. Surgical options can be used in operable cases of isolated head and neck metastases and radiotherapy options in cases with an inoperable focus (7, 10). It is important to note

that preoperative embolization may be necessary to reduce vascularity of the tumor in cases planned for surgery.

Treatment options in cases which disseminated metastasis is identified in metastatic screening is limited with palliative chemotherapy, hence metastasectomy not necessary (10). Although surgical procedures or radiotherapy can be used for head and neck metastases in such cases, it should be borne in mind that the treatment will not contribute to prognosis (3, 7). In our case, surgery or radiotherapy was not planned since there were other metastatic foci apart from the head and neck region. The patient was given palliative chemotherapy only and passed away in the first month of the treatment due to multiple organ failure.

Conclusion

Renal cell carcinoma most commonly metastasizes to the sinonasal region in the head and neck, and RCC is the most common metastatic tumor in the sinonasal region. In cases with RCC, treatment of the primary site together with metastasectomy should be used when an isolated head and neck metastasis is present, and palliative treatment options targeting the symptoms should be preferred in the presence of multiple organ metastases.

Informed Consent: Written informed consent was obtained from patient who participated in this study.

Peer-review: Externally peer-reviewed.

Author Contributions: Concept - M.A., M.C.E.; Design - M.A., M.C.E.; Supervision - M.C.E., M.A.; Resource - M.A., M.C.E.; Materials - M.A.; Data Collection and/or Processing - M.A.; Analysis and/or Interpretation - M.A., M.C.E.; Literature Search - M.A.; Writing - M.A., M.C.E.; Critical Reviews - M.C.E.

Conflict of Interest: No conflict of interest was declared by the authors.

Financial Disclosure: The authors declared that this study has received no financial support.

References

1. Lathi A, Syed MM, Kalakoti P, Qutub D, Kishve SP. Clinico-pathological profile of sinonasal masses: a study from a tertiary care hospital of India. *Acta Otorhinolaryngol Ital* 2011; 31: 372-7.
2. Prescher A, Brors D. Metastases to the paranasal sinuses: case report and review of the literature. *Laryngorhinootologie* 2001; 80: 583-94. [[CrossRef](#)]
3. Parida PK, Renal cell carcinoma metastatic to the sinonasal region: Three case reports with a review of the literature. *Ear Nose Throat J* 2012; 91: 11-6.
4. Gottlieb MD, Roland JT Jr. Paradoxical spread of renal cell carcinoma to the head and neck. *Laryngoscope* 1998; 108: 1301-5. [[CrossRef](#)]
5. Slootweg PJ, Ferlito A, Cardesa A, Thompson LD, Hunt JL, Stojan P, et al. Sinonasal tumors: a clinicopathologic update of selected tumors. *Eur Arch Otorhinolaryngol* 2013; 270: 5-20. [[CrossRef](#)]
6. Langille G, Taylor SM, Bullock MJ. Metastatic renal cell carcinoma to the head and neck: summary of 21 cases. *J Otolaryngol Head Neck Surg* 2008; 37: 515-21.
7. Pritchik KM, Schiff BA, Newkirk KA, Krowiak E, Deeb ZE. Metastatic renal cell carcinoma to the head and neck. *Laryngoscope* 2002; 112: 1598-602. [[CrossRef](#)]
8. Doğan S, Can IH, Sayın M, Ozer E, Bayız U, Yazici G, et al. The nasal septum: an unusual presentation of metastatic renal cell carcinoma. *J Craniofac Surg* 2009; 20: 1204-6. [[CrossRef](#)]
9. Hong SL, Jung DW, Roh HJ, Cho KS. Metastatic renal cell carcinoma of the posterior nasal septum as the first presentation 10 years after nephrectomy. *J Oral Maxillofac Surg* 2013; 71: 1813.e1-7.
10. Russo P, O'Brien MF. Surgical intervention in patients with metastatic renal cancer: metastasectomy and cytoreductive nephrectomy. *Urol Clin North Am* 2008; 35: 679-86. [[CrossRef](#)]