






Myxoma of the Middle Ear Mimicking Chronic Otitis Media

Yüksel Olgun¹ , Melih Arif Közen¹ , Ayça Erşen Danyeli² , Sülen Sarıoğlu² , Enis Alpin Güneri¹ 

Case Report

¹Department of Otorhinolaryngology, Dokuz Eylül University School of Medicine, İzmir, Turkey

²Department of Pathology, Dokuz Eylül University School of Medicine, İzmir, Turkey

Abstract

Myxoma is a benign connective tissue tumor that arises mostly from the heart. Temporal bone myxomas are extremely rare and these patients should be evaluated for the Carney complex association. Herein, our aim was to present a middle ear myxoma case operated with an initial diagnosis of chronic otitis me-

dia (COM) and to underline the fact that myxomas should be kept in mind in the differential diagnosis of aural polyps.

Keywords: Myxoma, aural polyp, chronic otitis media, Carney complex

Introduction

Myxoma is a rare benign connective tissue neoplasm originating mostly from the heart (1). It can also arise from the head and neck region especially from the mandible and maxilla (2). Although very rarely encountered, myxomas can be seen in different parts of the temporal bone and other parts of the head and neck region (1-8). Myxoma of the temporal bone may present as a polypoid mass with local destructive properties (3, 4). Herein, our aim was to present a middle ear myxoma case which was operated with an initial diagnosis of chronic otitis media (COM) and underline the fact that myxomas should be kept in mind in the differential diagnosis of polypoid ear masses.

Case Presentation

A 47-year-old male patient was referred to our clinic with complaints of recurrent otorrhea and hearing loss for more than 10 years in his right ear. Otomicroscopic examination revealed a large tympanic membrane perforation in the right ear and a polypoid mass arising from the middle ear cavity. In the pure tone audiometry, the patient had a conductive hearing loss with an air-bone gap of 40 dB (PTA average 0.5- 3 kHz). Temporal com-

puted tomography (CT) scans revealed a diffuse aeration loss in the middle ear and mastoid cells and a soft tissue mass arising from the middle ear that extended to external ear canal (Figure 1).

Biopsy of the polypoid mass was reported as a mucosal polyp rich in plasma cells. In the microscopic examination of the specimen, a polypoid mass surrounded by pseudostratified epithelium rich in plasma cells, Russel bodies and lymphocytes was observed. Thereafter, tympanomastoidectomy was planned with the diagnosis of COM with cholesteatoma. During the operation a whitish ovoid polypoid mass was observed, which was filling the middle ear cavity and easily dissected from middle ear mucosa. After removal of the mass, the appearance of the middle ear mucosa was healthy and no cholesteatoma was seen. Then we performed an epitympanotomy in order to expose the attic region but no signs of cholesteatoma and/or polypoid mass were seen. Malleus and stapes were intact, but the lenticular process of incus was eroded (Austin Kartush classification type A). The defect between the incus and stapes head was reconstructed by using glass ionomer bone cement, and a cartilage island tympanoplasty was performed.



ORCID IDs of the authors:
Y.O. 0000-0003-1769-4224;
M.A.K. 0000-0003-0429-1602;
A.E.D. 0000-0001-8015-9916;
S.S. 0000-0003-4877-3064;
E.A.G. 0000-0003-2592-0463.

Cite this article as: Olgun Y, Közen MA, Erşen Danyeli A, Sarıoğlu S, Güneri EA. Myxoma of the Middle Ear Mimicking Chronic Otitis Media Turk Arch Otorhinolaryngol 2018; 56: 47-50.

This study was presented at the ENT World Congress IFOS, June 24-28, 2017, Paris, France.

Corresponding Author:
Yüksel Olgun
E-mail: yuksel.olgun@deu.edu.tr

Received Date: 25.08.2017
Accepted Date: 24.10.2017

© Copyright 2018 by Official Journal of the Turkish Society of Otorhinolaryngology and Head and Neck Surgery Available online at www.turkarchotolaryngol.net
DOI: 10.5152/tao.2018.2754

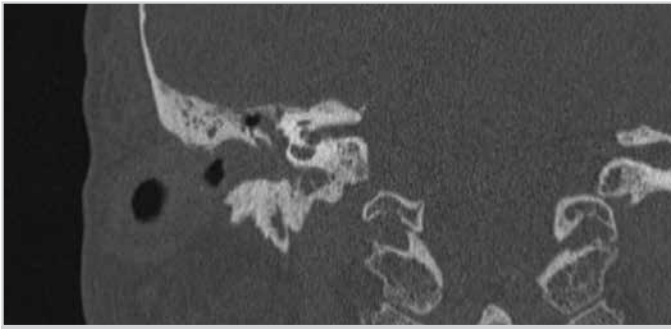


Figure 1. Preoperative coronal section temporal CT scan showing a soft tissue density in the middle ear cavity extending to the external ear canal

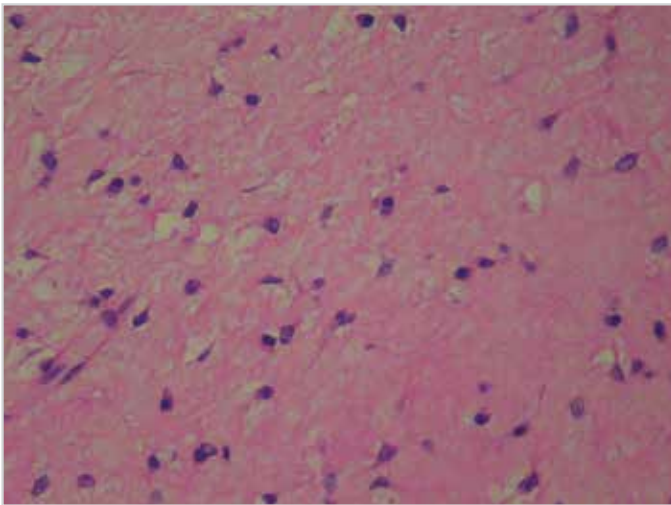


Figure 2. Beneath the respiratory type epithelium, rare benign stellate cells and inflammatory cells are readily seen (H&E, original magnification X40)

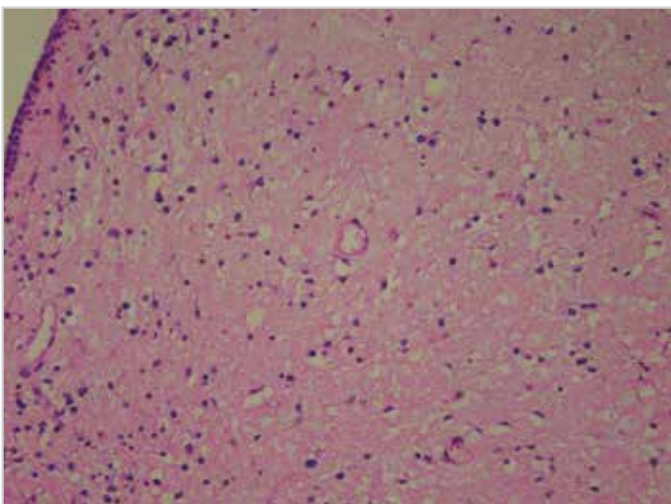


Figure 3. Beneath the respiratory type epithelium, rare benign stellate cells and inflammatory cells are readily seen (H&E, original magnification X10)

Microscopic examination revealed submucosal S100 positive, EMA, CD34, synaptophysin, CD56, CD57, GFAP, P53 negative spindle or stellate cells observed in a myxoid matrix. The

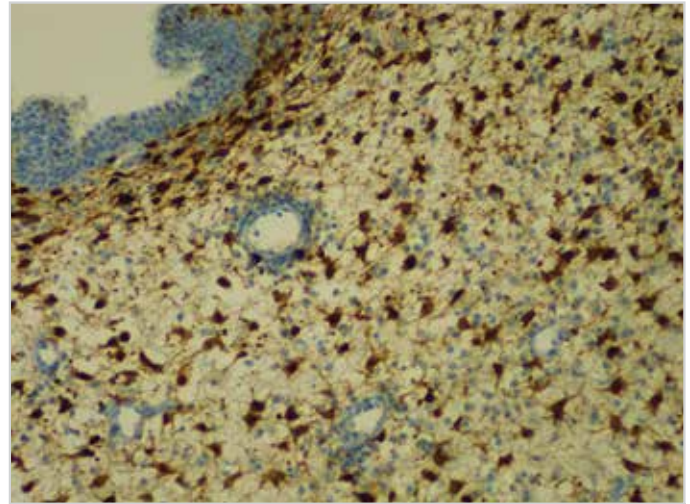


Figure 4. The stellate cells show strong S100 positivity (immunohistochemistry; S100) (magnification X20)

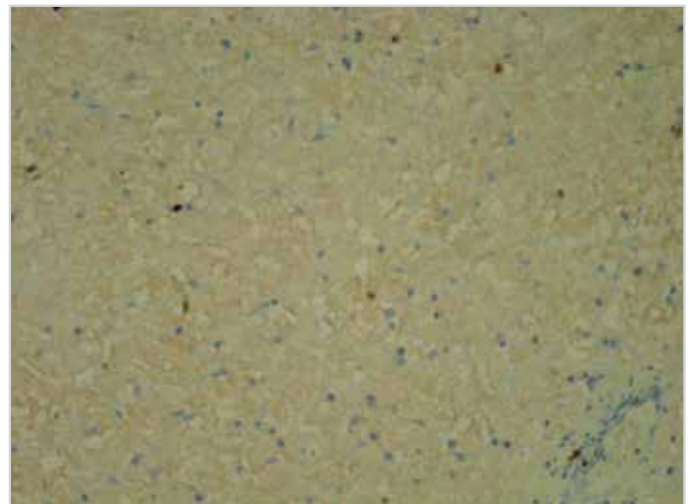


Figure 5. Few cells exhibit Ki67 immunoreactivity (low proliferative activity) (immunohistochemistry; Ki67) (original magnification X20)

ki-67 proliferative activity was quite low (Figure 2-5). With these pathologic features, the final evaluation of the polypoid mass was reported as myxoma. The patient consulted with Cardiology, Endocrinology and Dermatology departments and was evaluated for the Carney complex. Echocardiography, thyroid and scrotal ultrasonography, abdomen CT, hypophysis magnetic resonance imaging (MRI) studies were completed and their results were all normal with the exception of a non-functional pituitary microadenoma, which was eight mm in diameter. Eventually it was concluded that the patient did not have Carney complex.

Our preoperative clinical diagnosis was COM with cholesteatoma due to the existence of a non-specific polypoid mass in the middle ear and a history of recurrent otorrhea. In preoperative CT scans of the patient, some soft tissue density and aeration loss was observed in mastoid cells, but as our initial diagnosis was chronic otitis media and we did not observe any signs of cholesteatoma in the middle ear cavi-

ty and attic region after clearance of the polypoid mass, we did not explore the mastoid region. However, the biopsy of the polypoid mass was resulted as myxoma. For this reason, we decided to explore the middle ear and mastoid cavity in order to rule out any residual tumor as soon as possible and investigate the patient for possible Carney complex association. Temporal magnetic resonance imaging was completed at the second postoperative month, which revealed some loss of aeration in the mastoid cells. Then a canal wall up mastoidectomy was performed as a second look, but we did not observe any signs of residual tumor in mastoid cells and middle ear cavity. No signs of recurrence were seen after a follow-up period of 17 months, and the patient's postoperative pure tone audiometry result was normal. Written informed consent was obtained from the patient prior to retraction of this manuscript.

Discussion

Myxomas are rare benign tumors arising mostly from the connective tissues of the heart. The head and neck region, mandible and maxilla (2, 3) are the most common sites of involvement. However, they may arise from different parts of the temporal bone such as the ear lobule, external auditory canal, or middle ear (1, 4, 7).

Myxomas of the temporal bone may have local destructive properties causing otorrhea, hearing loss, headache and facial palsy depending on the site of involvement (1, 3, 7). Surgery is considered as the first choice of treatment, because the myxomas are not radiosensitive (4, 8). Although we did not observe any local destructive properties in the CT scan, we noted an erosion in the lenticular process of incus intraoperatively and we reconstructed this defect using bone cement.

Temporal bone myxomas may be related to the Carney complex in some cases, characterized by various cardiac and cutaneous myxomas, melanotic schwannomas, endocrine tumors and cutaneous pigmentary manifestations (1-3, 7). Carney complex is inherited autosomal dominantly and PRKAR1A gene mutations or deletions are seen in patients (3). Early detection of cardiac myxomas is mandatory because they may lead to fatal conditions such as cardiac embolisms. Our case was a healthy male patient without any history of possible cardiac involvement but it was consulted with Cardiology, Endocrinology and Dermatology departments, eventually ruling out of existence of a Carney complex.

Aural polyps are mostly encountered with chronic suppurative otitis media. In a study conducted on 42 patients with aural polyps, 88% of the cases were related to tubotympanic otitis media, but in 12% of the cases cholesteatoma was the underlying pathology (9). However, it should be kept in mind that aural polyps may be related to serious pathologies other than COM as seen in our case. Xenellis et al. (10) reported that, among the patients they operated on with an initial diagnosis of COM and

with a polypoid mass in the external ear canal, cholesteatoma was the main pathology in the majority of the cases (86.7%). However, other lesions like glomus tumor, melanoma, mucosal adenoma, fibrous dysplasia, squamous cell carcinoma, adenoma of the endolymphatic sac, encephalocele, and tuberculosis were reported in the remaining patients. Solitary middle ear myxoma is extremely rare with only a few cases described in the literature (2, 4, 5, 7). Due to its morphological characteristics (polypoid mass) and symptoms such as hearing loss, recurrent otorrhea, and facial palsy it could easily be misdiagnosed clinically as a case of COM.

Conclusion

Myxomas should be kept in mind in the differential diagnosis of patients with aural polyps. Besides, all patients diagnosed with myxomas should also be evaluated for the possible association of the Carney complex.

Informed Consent: Written informed consent was obtained from patient who participated in this study.

Peer-review: Externally peer-reviewed.

Author Contributions: Concept - Y.O., A.E.D., M.A.K., E.A.G., S.S.; Design - Y.O., A.E.D., M.A.K., E.A.G., S.S.; Supervision - E.A.G., S.S., Y.O., A.E.D., M.A.K.; Resource - A.E.D., S.S., Y.O.; Materials - Y.O., A.E.D., S.S.; Data Collection and/or Processing - Y.O., M.A.K.; Analysis and/or Interpretation - Y.O.; Literature Search - Y.O., M.A.K.; Writing - Y.O.; Critical Reviews - E.A.G., S.S.

Conflict of Interest: No conflict of interest was declared by the authors.

Financial Disclosure: The authors declared that this study has received no financial support.

References

1. Lee DH, Jeong SH, Kim H, Shin E. Isolated myxoma in the external auditory canal of a 10 year old girl. *J Int Adv Otol* 2015; 11: 264-6. [\[CrossRef\]](#)
2. Hsieh DL, Tseng HM, Young YH. Audiovestibular evolution in a patient undergoing surgical resection of a temporal bone myxoma. *Eur Arch Otorhinolaryngol* 2006; 263: 614-7. [\[CrossRef\]](#)
3. Shadfar S, Scanga L, Dodd L, Buchman CA. Isolated myxoma of the external auditory canal. *Laryngoscope* 2014; 124: 1220-2 [\[CrossRef\]](#)
4. Abboud O, Saliba I. Middle ear myxoma. *Otolaryngol Head and Neck Surg* 2012; 147: 590-1. [\[CrossRef\]](#)
5. Sareen D, Sethi A, Mrig S, Nigam S, Agarwal AK. Myxoma of the temporal bone: an uncommon neoplasm. *Ear Nose Throat J* 2010; 89: 18-20.
6. Hoshino T, Hamada N, Seki A, Ogawa H. Two cases of myxoma of the external auditory canal. *Auris Nasus Larynx* 2012; 39: 620-2. [\[CrossRef\]](#)
7. Zehlicke T, Punke C, Boltze C, Pau HW. Transient facial palsy in two cases of benign, very rare middle ear tumors (carcinoid tumor and myxoma). *Neurologist* 2008; 14: 52-5. [\[CrossRef\]](#)

8. Orhan KS. A rare cause of unilateral nasal mass: Skull base myxoma. *Turk Arch Otorhinolaryngol* 2011; 49: 36-39. [\[CrossRef\]](#)
9. Prasannaraj T, De NS, Narasimhan I. Aural polyps: safe or unsafe disease? *Am J Otolaryngol* 2003; 24: 155-8. [\[CrossRef\]](#)
10. Xenellis J, Mountricha A, Maragoudakis P, Kandiloros D, Assimakopoulos D, Linthicum FJ, et al. A histological examination in the cases of initial diagnosis as chronic otitis media with a polypoid mass in the external ear canal. *Auris Nasus Larynx* 2011; 38: 325-8. [\[CrossRef\]](#)